

# Anatomy for 3D Transesophageal Echocardiography

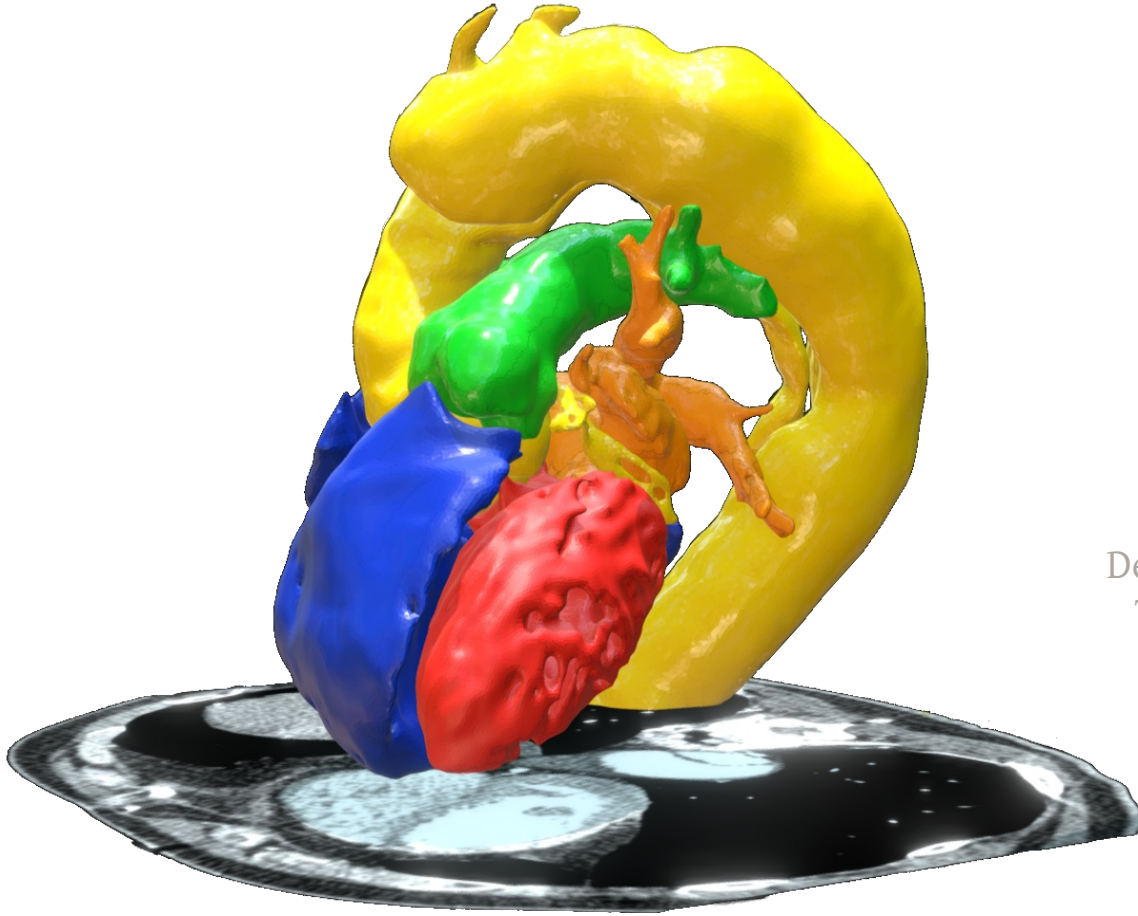
2019.11.01


**Azad Mashari**

Department of Anesthesiology & Pain Management  
Toronto General Hospital, University of Toronto

**Massimiliano Meineri**

Department of Anesthesia & Intensive Care  
Herzzentrum Leipzig, Germany





This work is licensed under a Creative Commons Attribution 4.0 International License.

For details see: <https://creativecommons.org/licenses/by/4.0>

### You are free to:

- **Share** — copy and redistribute the material in any medium or format
- **Adapt** — remix, transform, and build upon the material

for any purpose, even commercially.

The licensor cannot revoke these freedoms as long as you follow the license terms.

### Under the following terms:

- **Attribution** — You must give appropriate credit, provide a link to the license, and indicate if changes were made. You may do so in any reasonable manner, but not in any way that suggests the licensor endorses you or your use.
- **No additional restrictions** — You may not apply legal terms or technological measures that legally restrict others from doing anything the license permits.

#### Notices:

- 1) You do not have to comply with the license for elements of the material in the public domain or where your use is permitted by an applicable exception or limitation.
- 2) No warranties are given. The license may not give you all of the permissions necessary for your intended use. For example, other rights such as publicity, privacy, or moral rights may limit how you use the material.

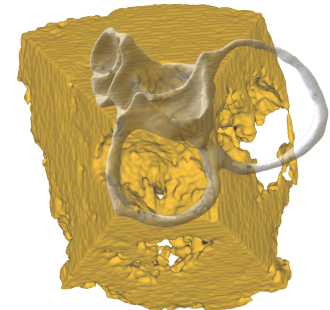
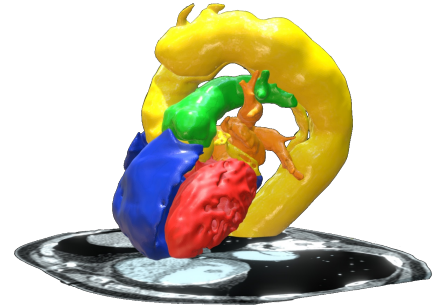
# Conflict of Interest

No conflicts of interest with respect to the content of this presentation.

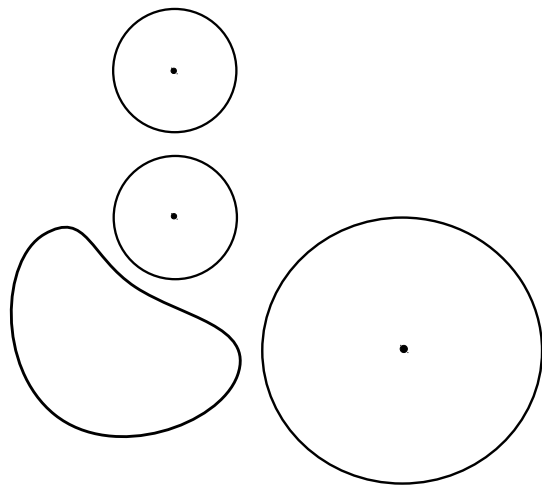
Research funding from Peter Munk Cardiac Center Foundation.

# Objectives

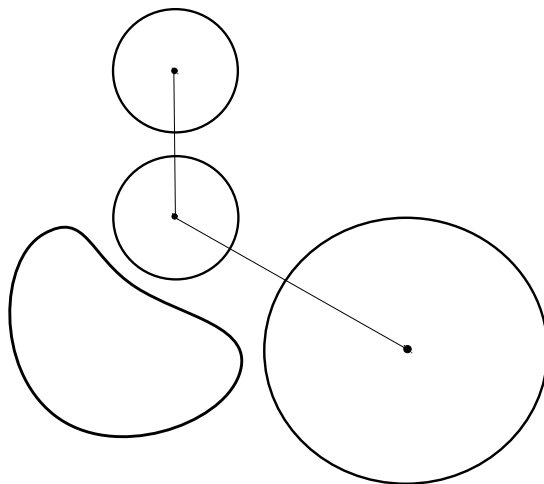
1. Visualize the structure, position and orientation of the **heart base** in the thorax
2. Visualize the chambers, great vessels in relation to the heart base
3. Position common 3D views in relation to the heart base



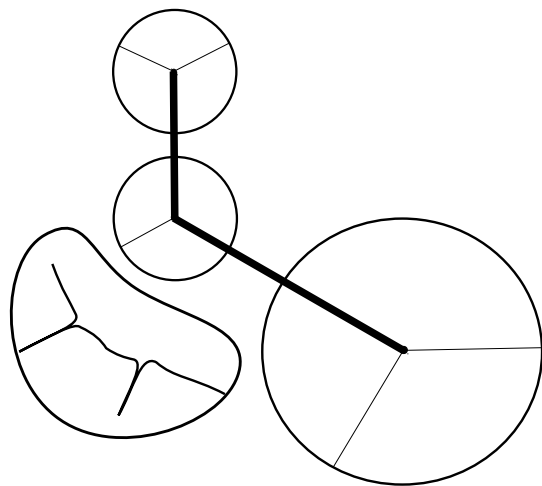
*1*

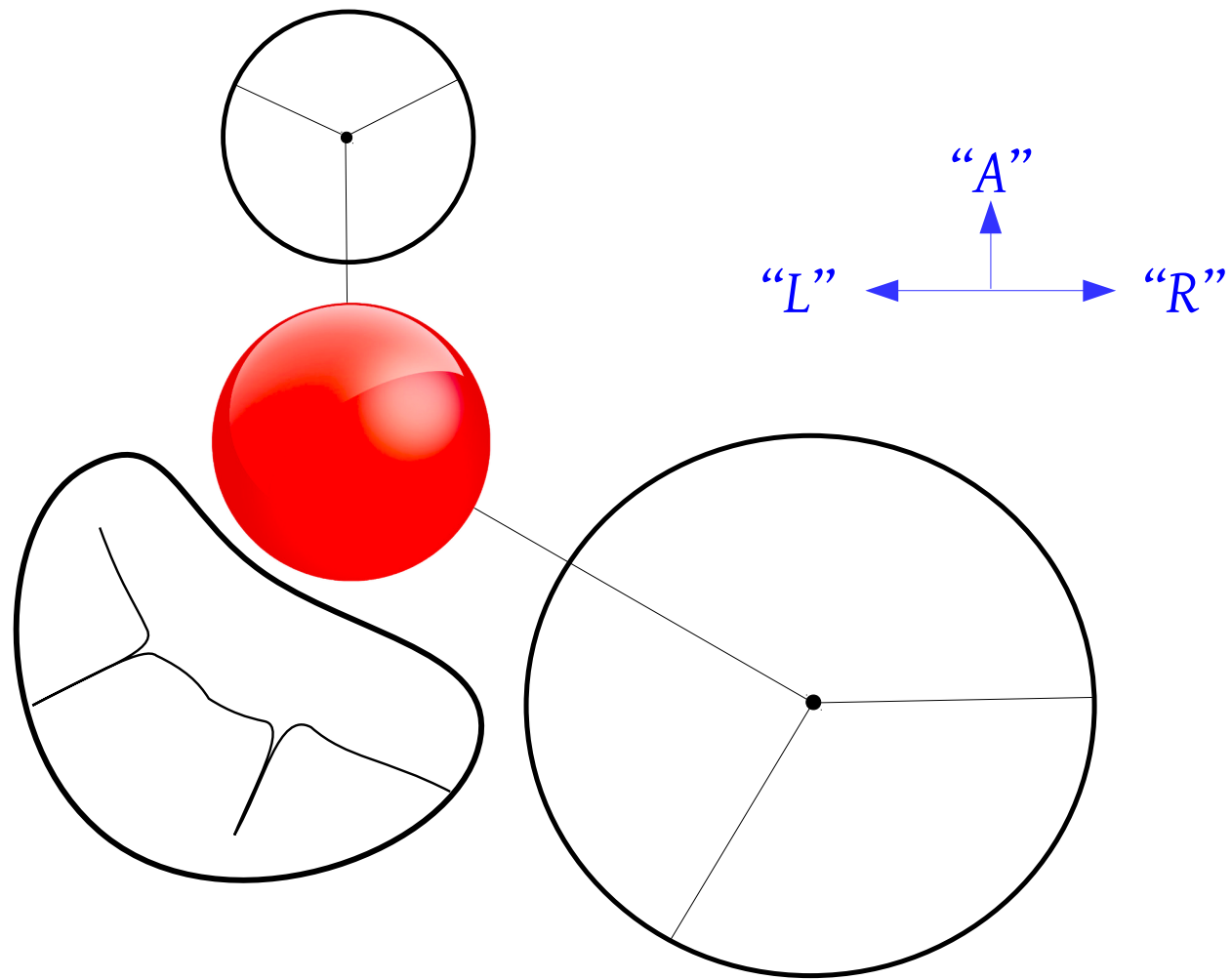


2



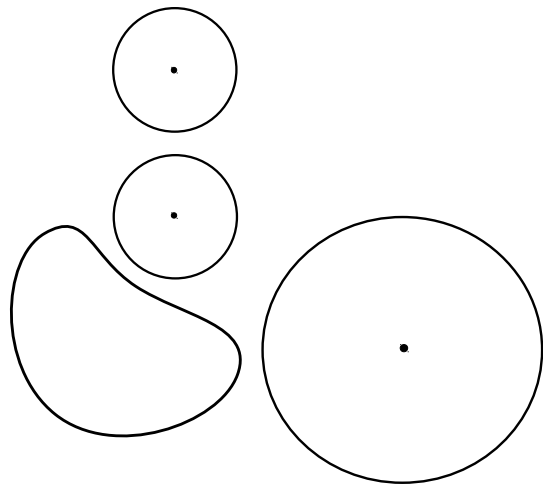
3



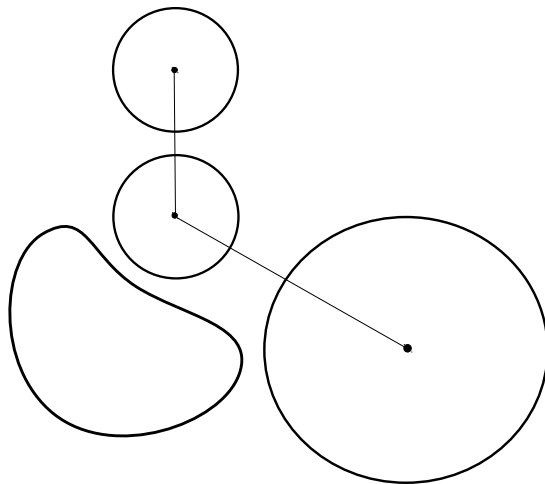




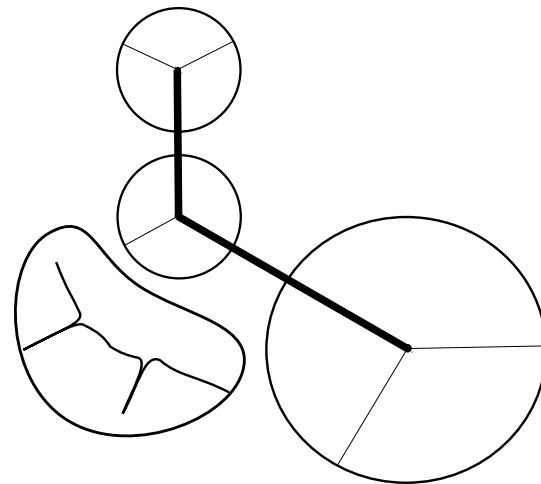
1



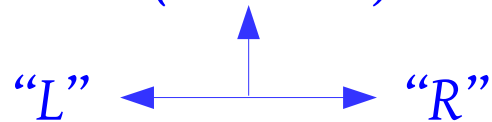
2

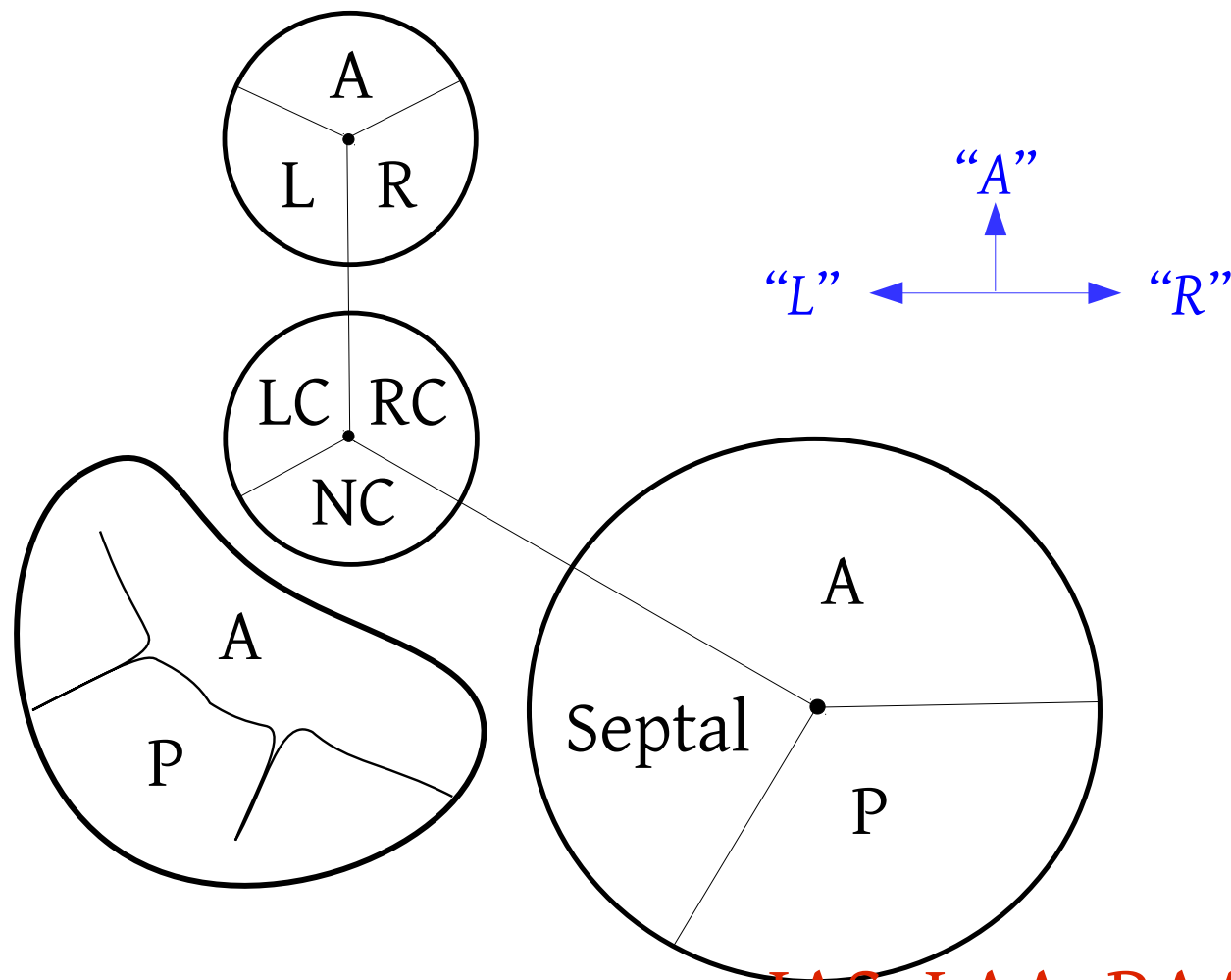


3

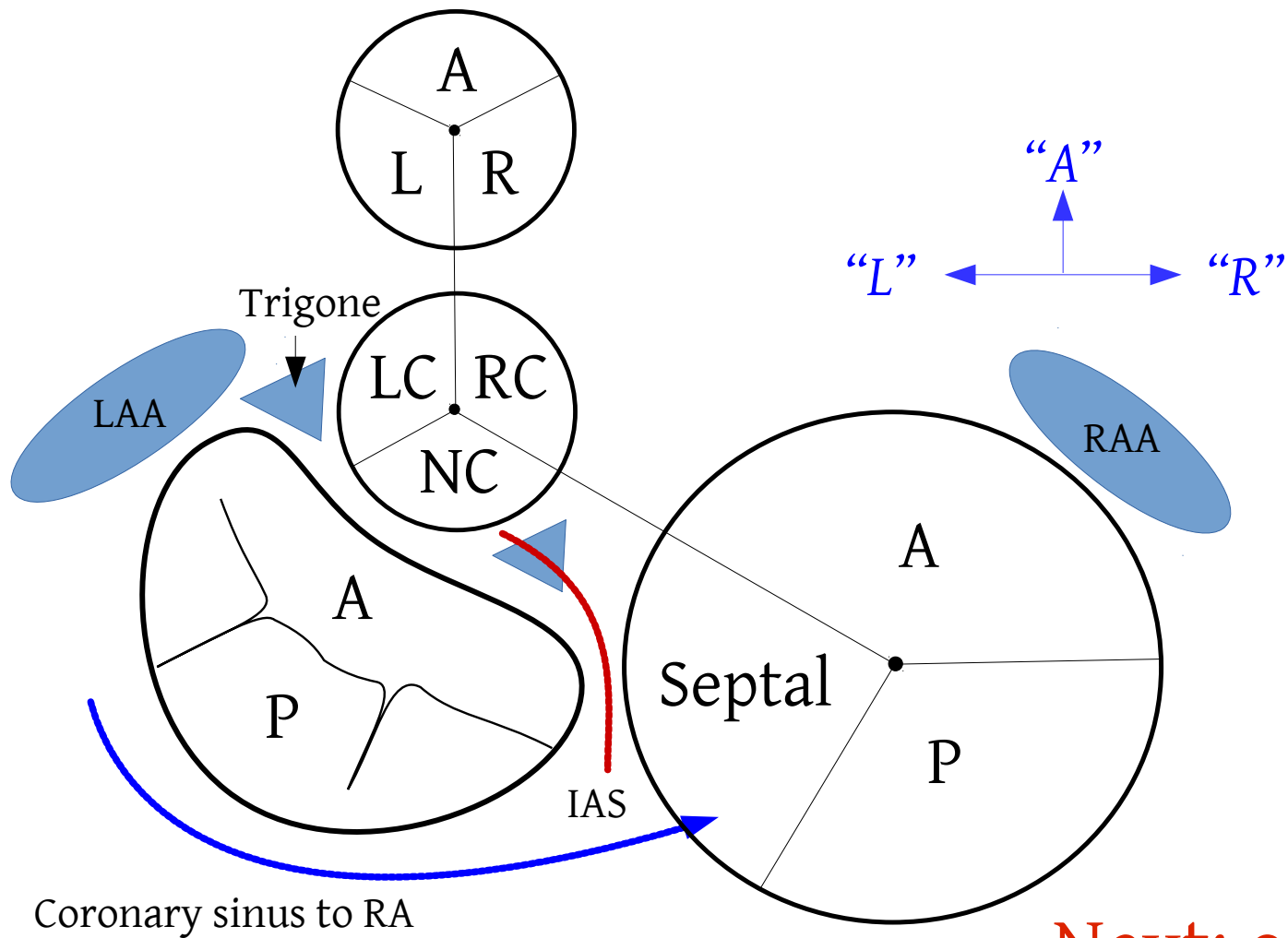


*A (Sternum)*

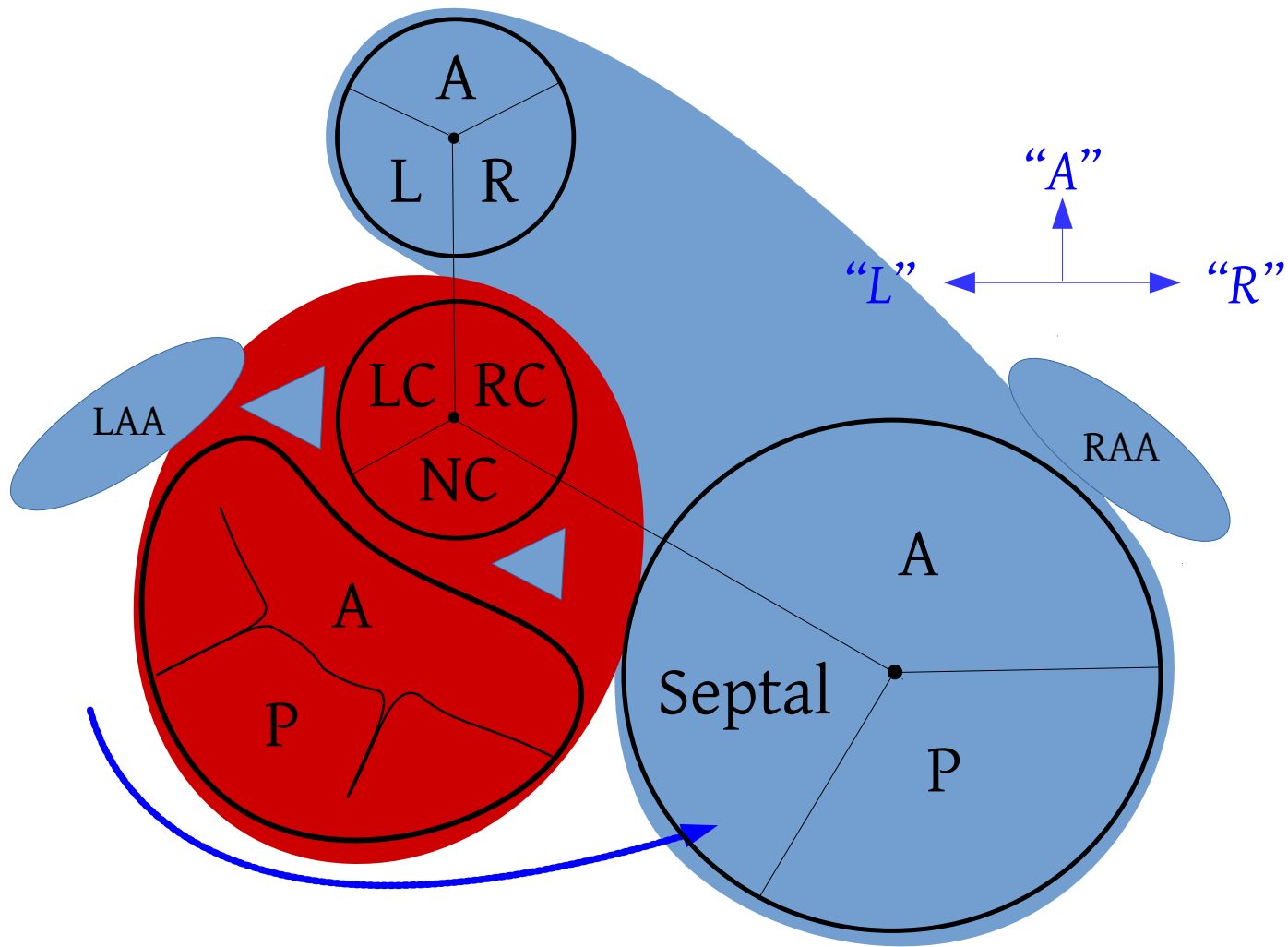


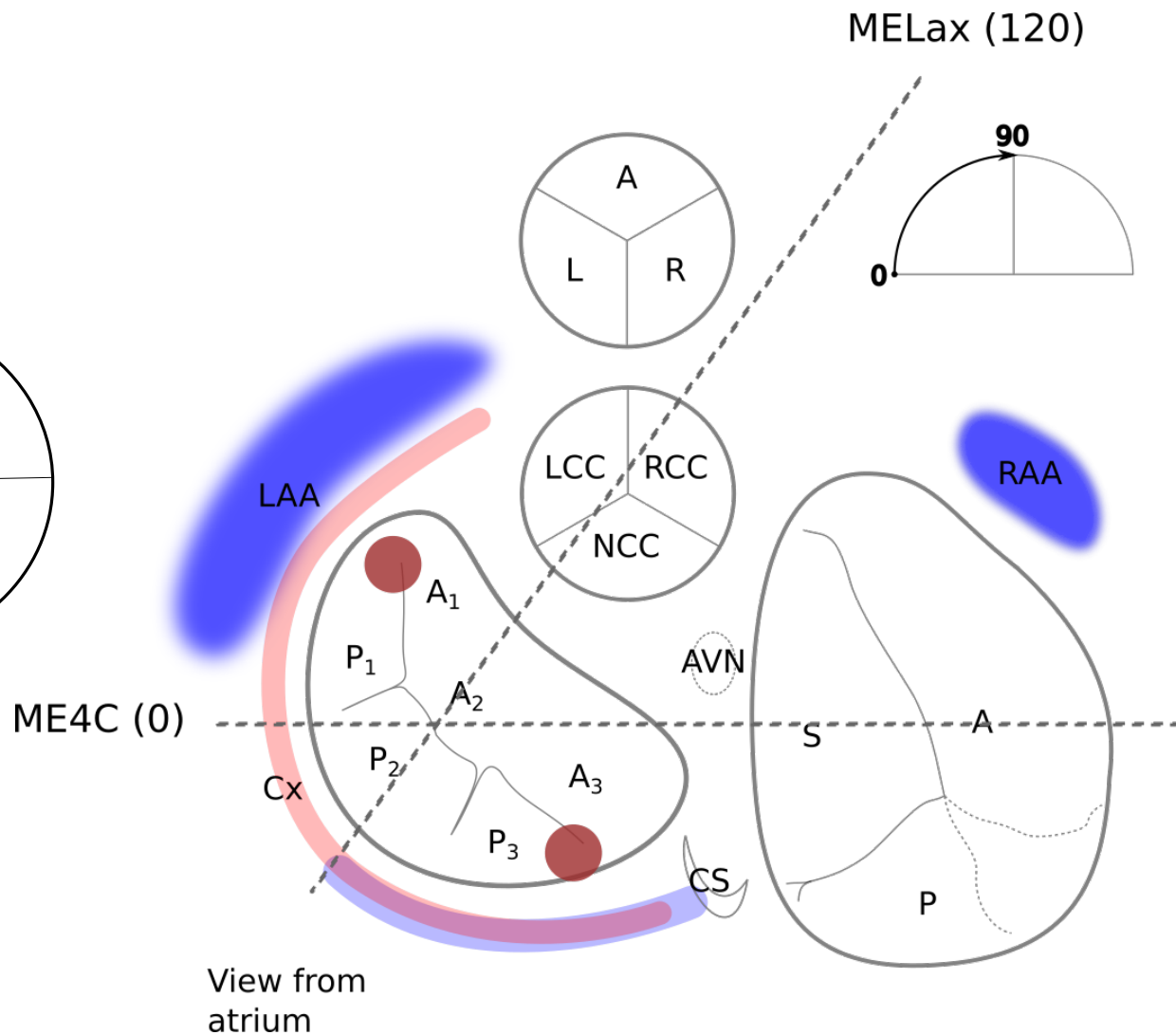
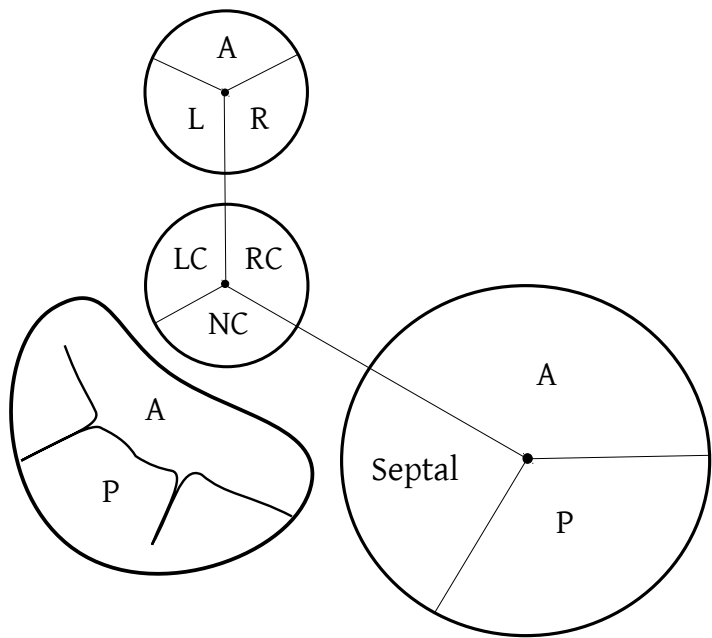


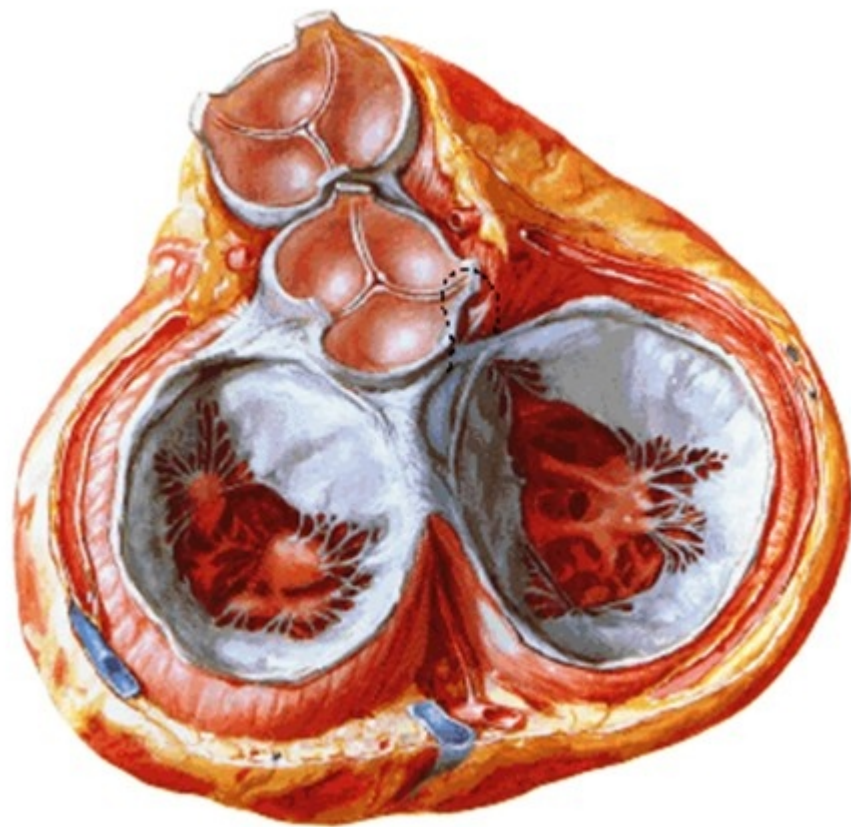
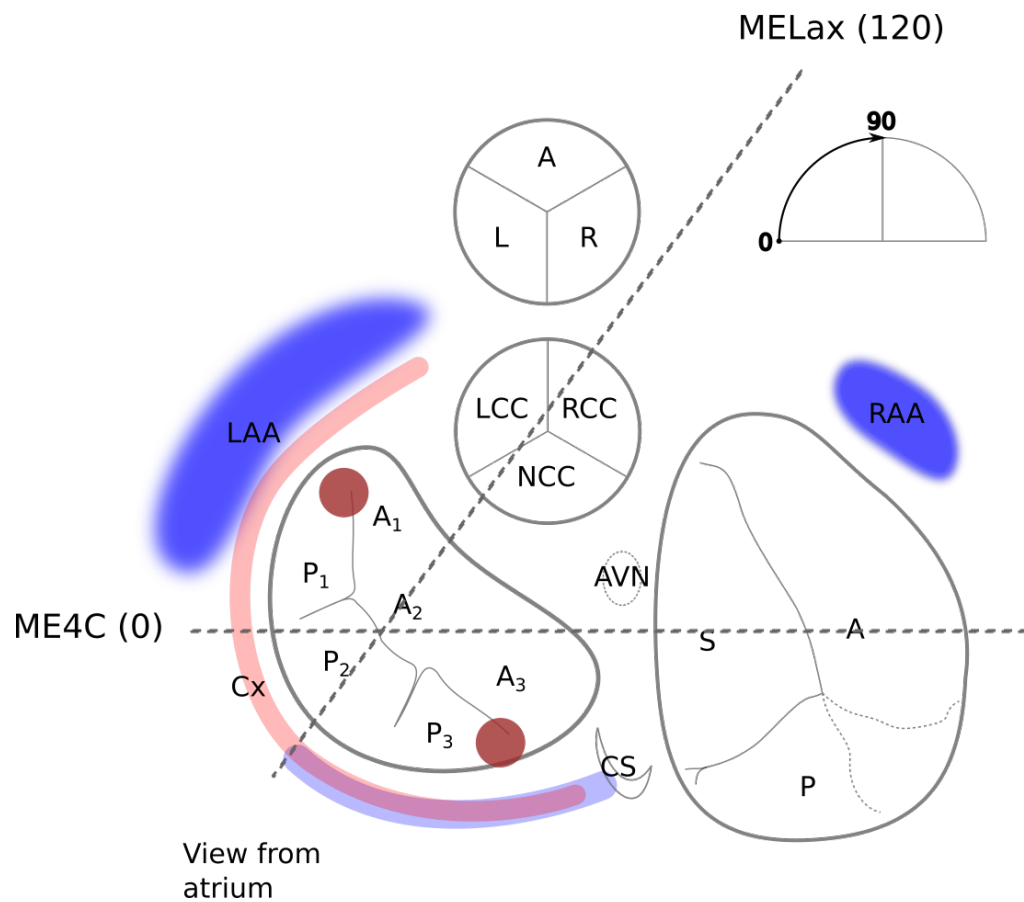
... IAS, LAA, RAA, Coronary sinus



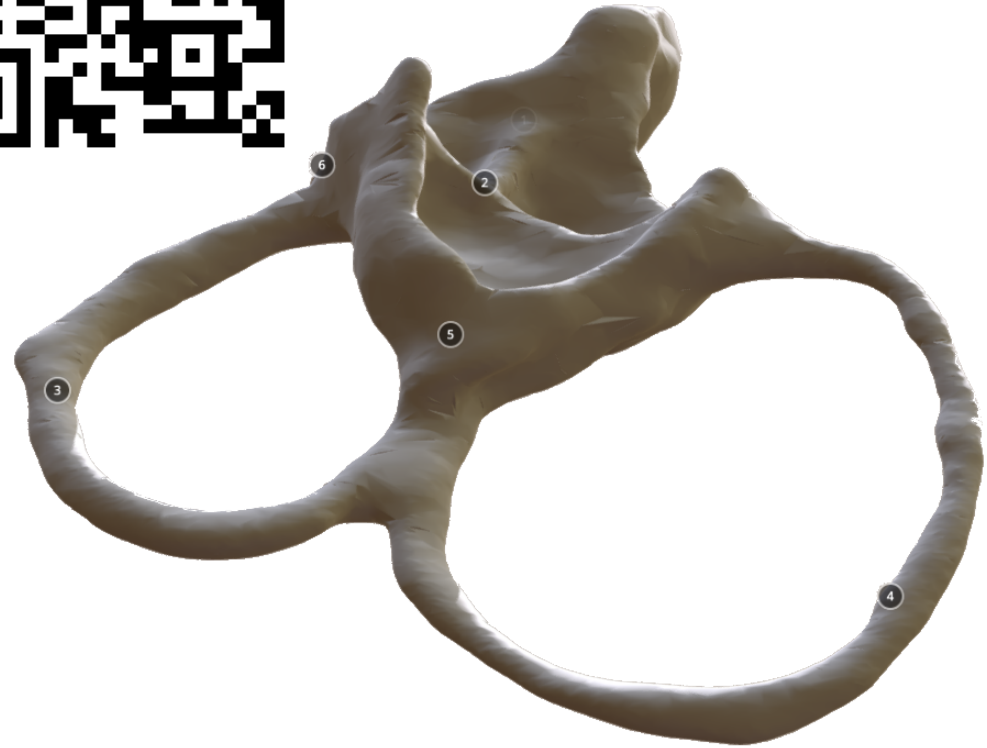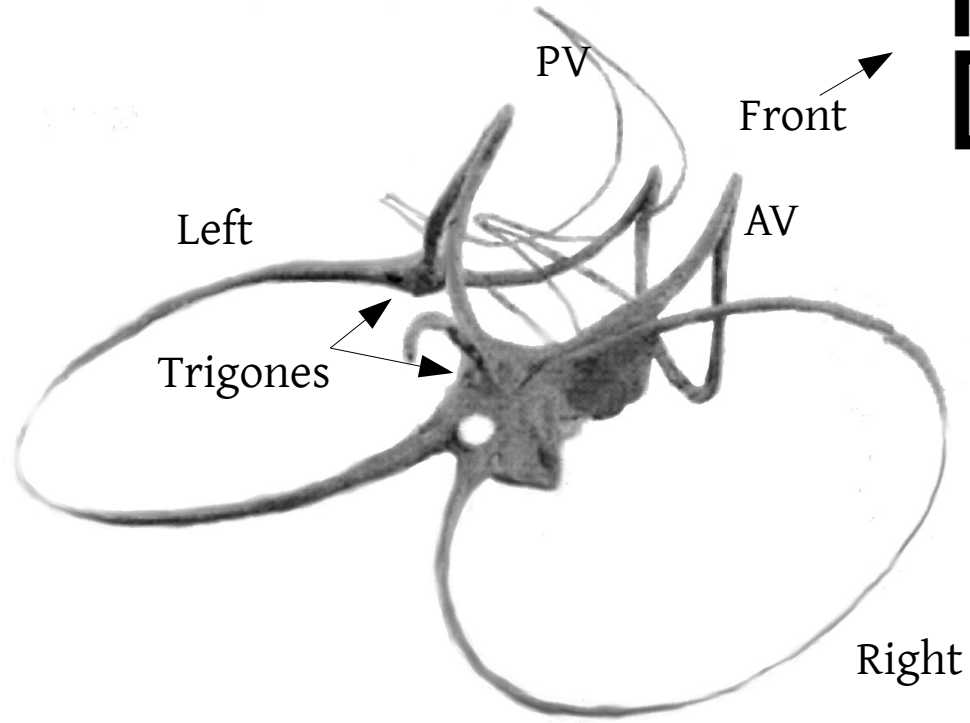
Next: outline of RV/ LV







# Fibrous Skeleton

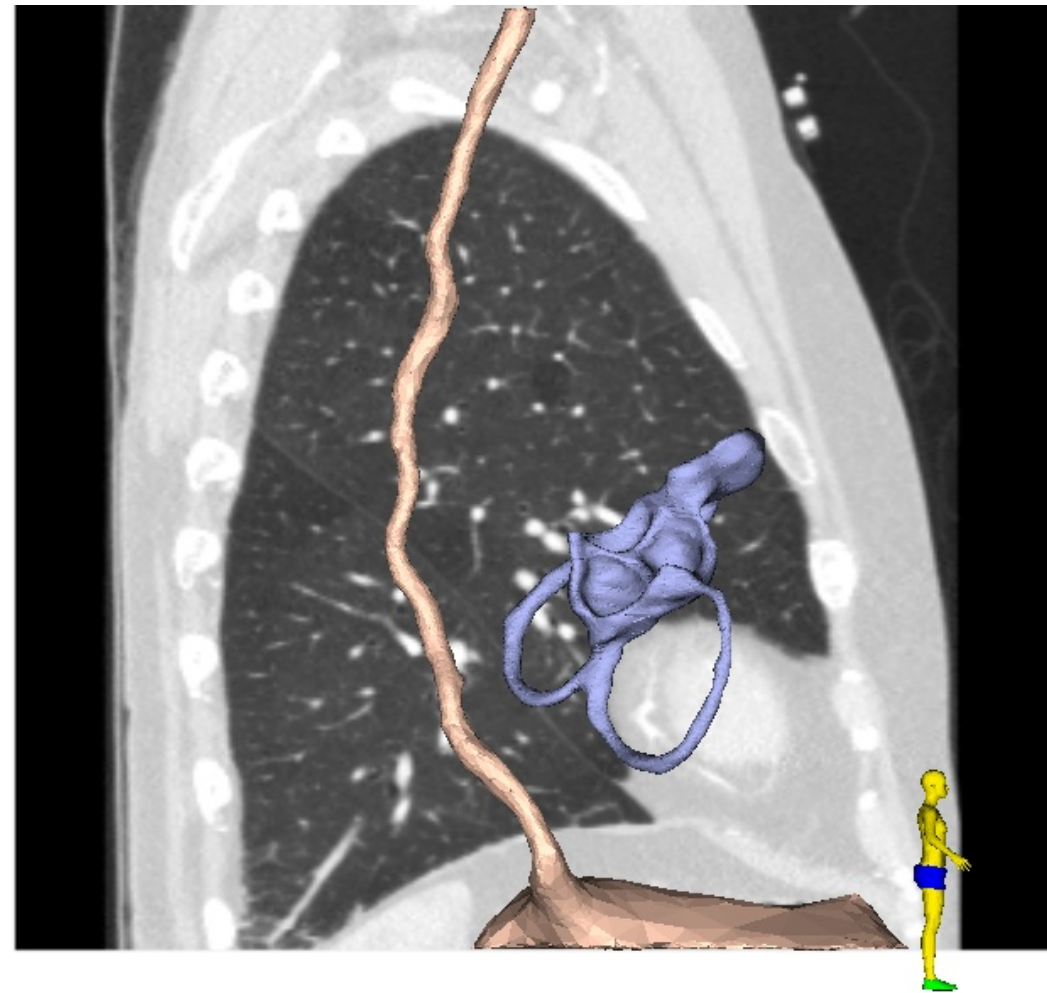
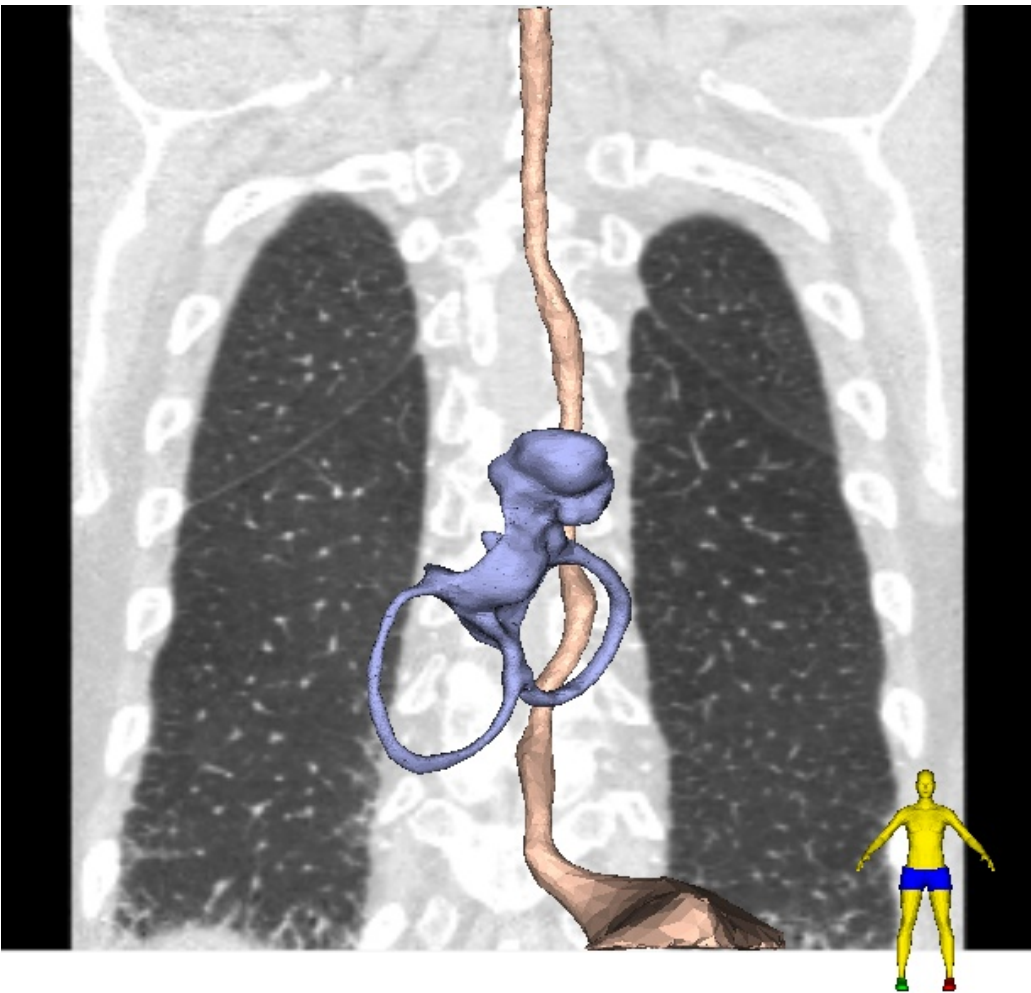


Zimmerman (1966)

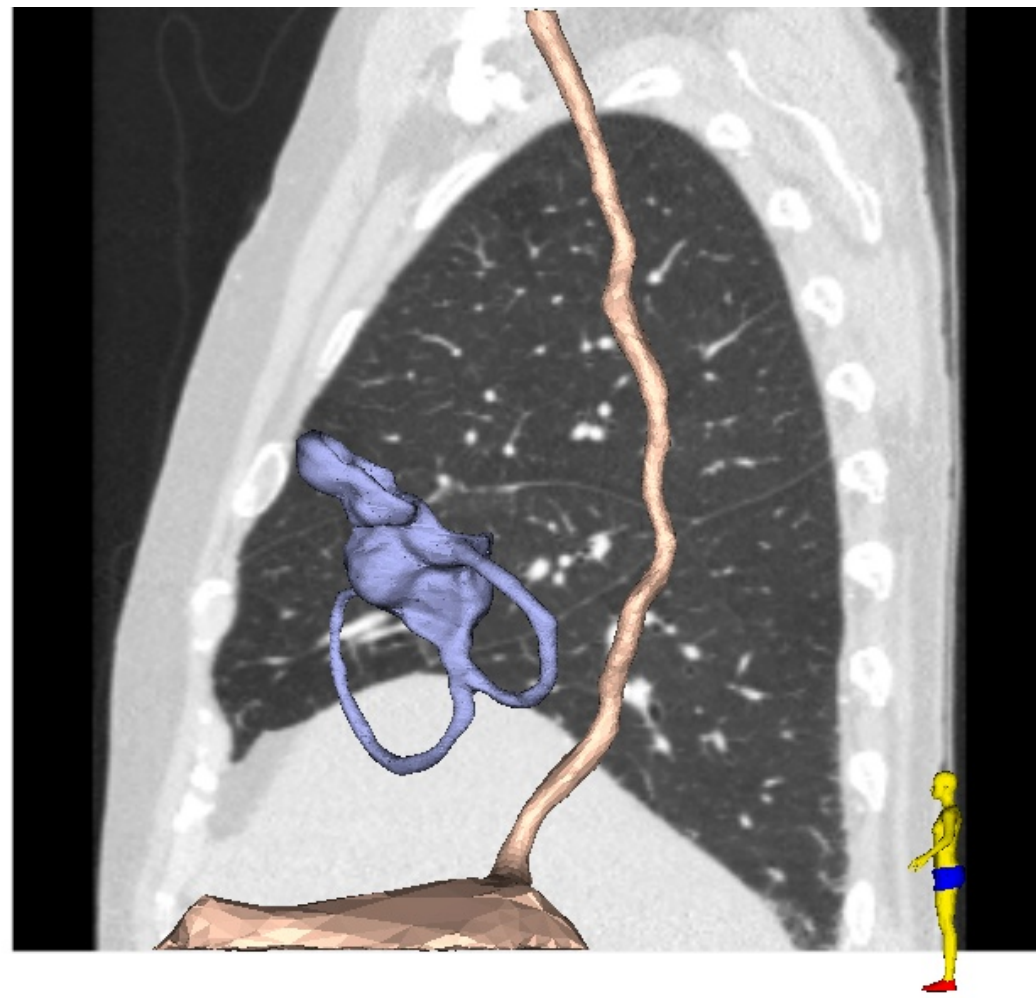
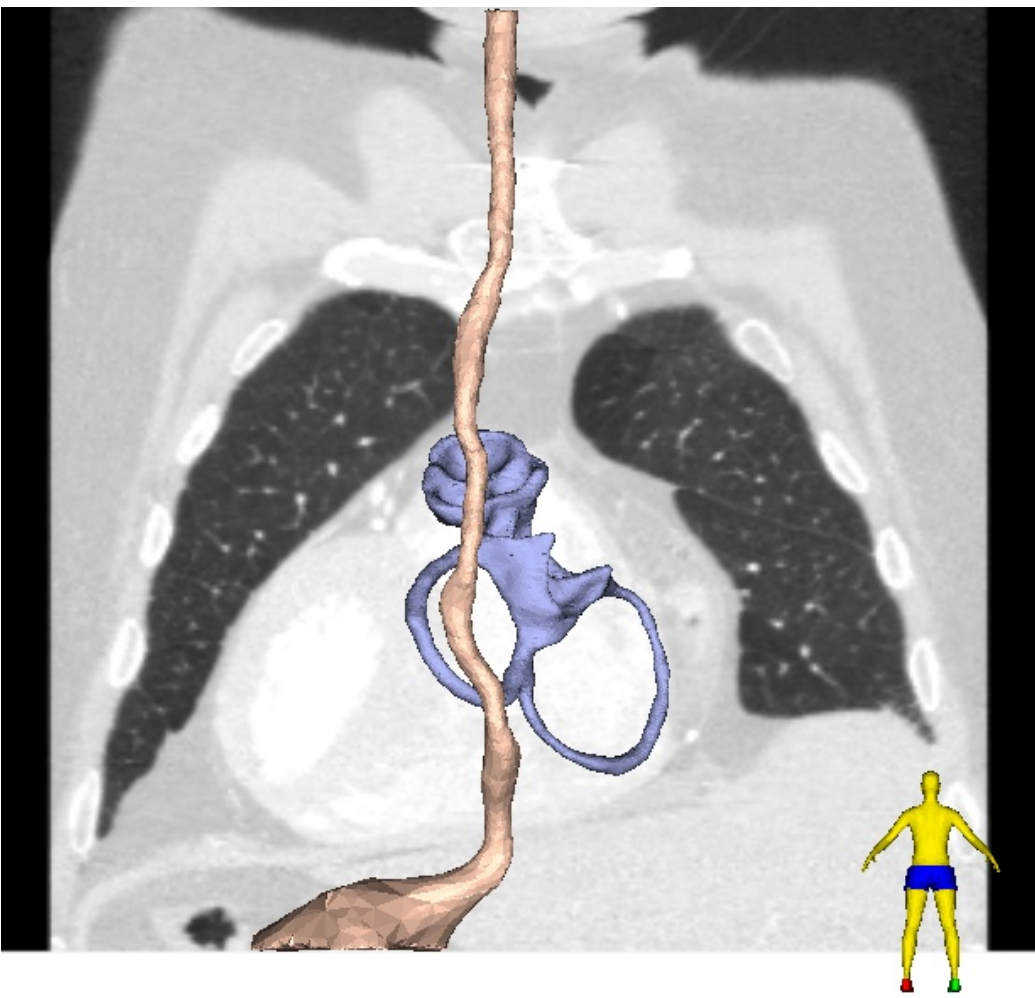




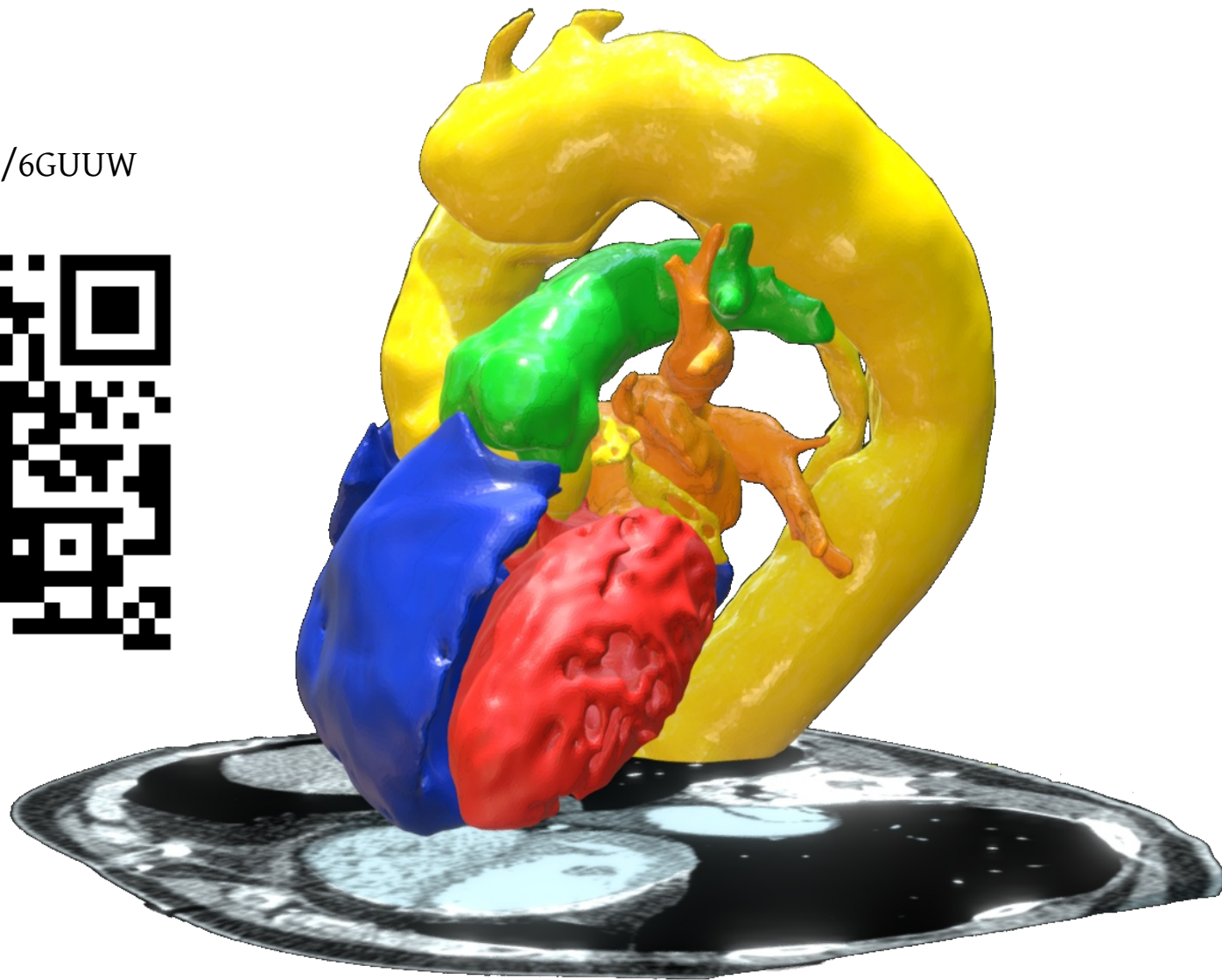
# Position of the heart base in the thorax



# Position of the heart base in the thorax

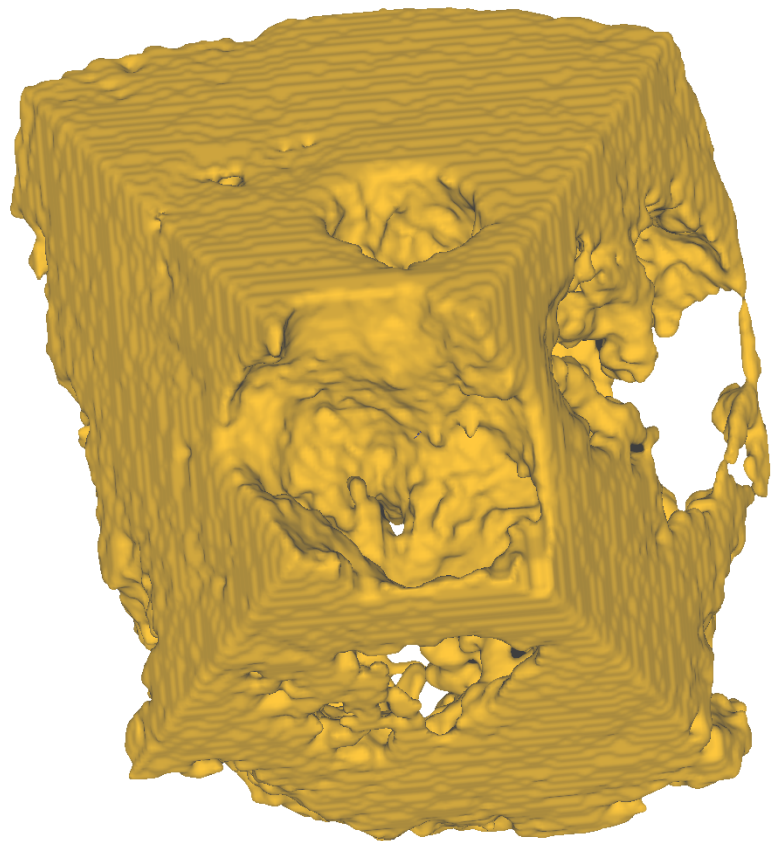


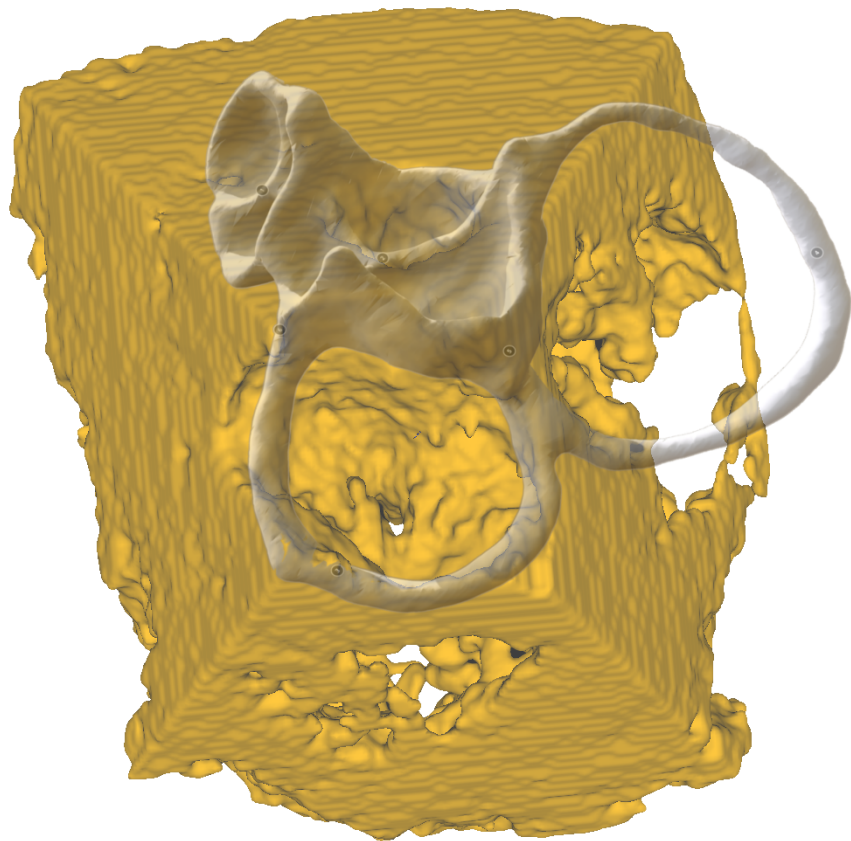
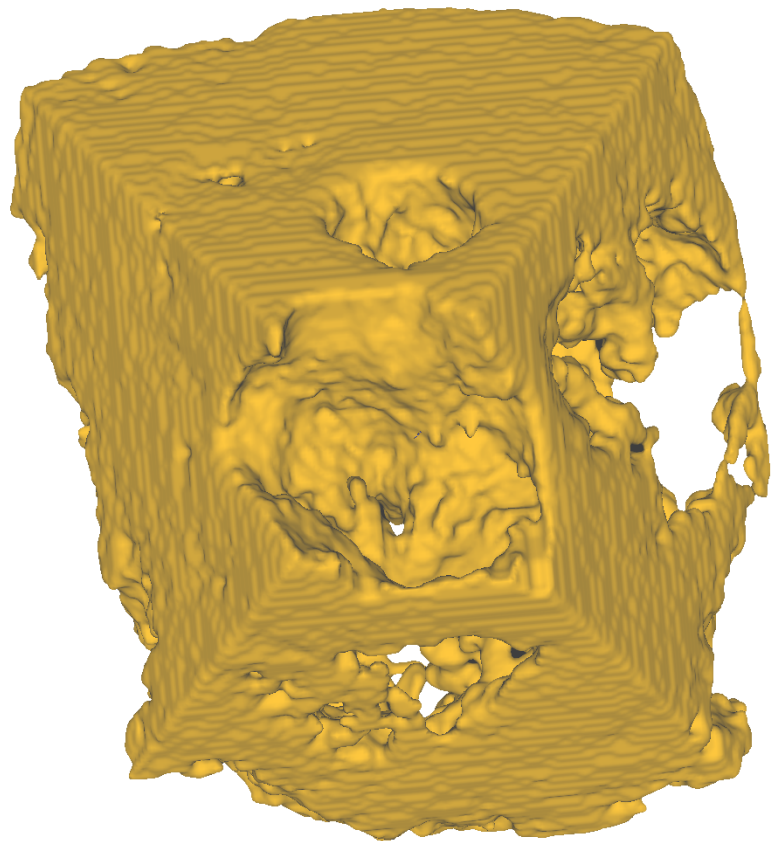
<https://skfb.ly/6GUUW>

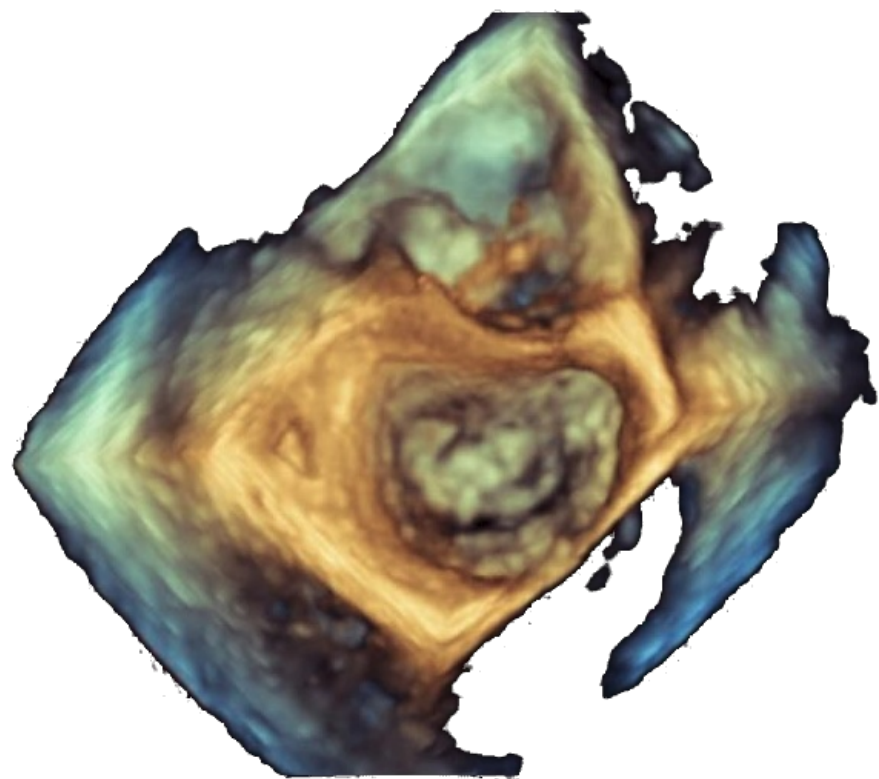


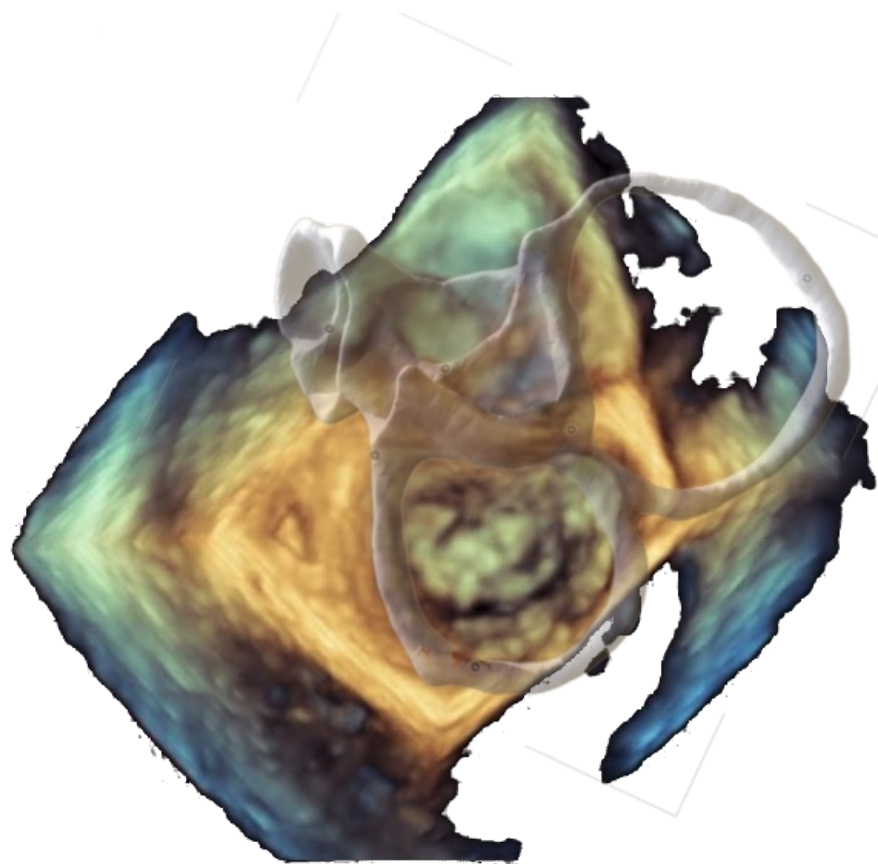
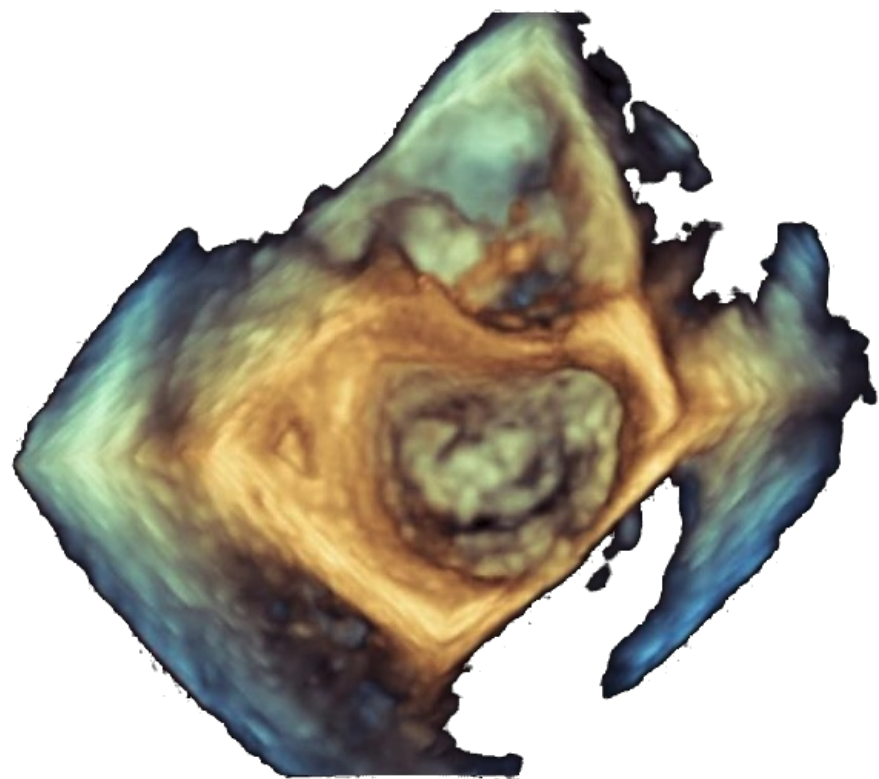




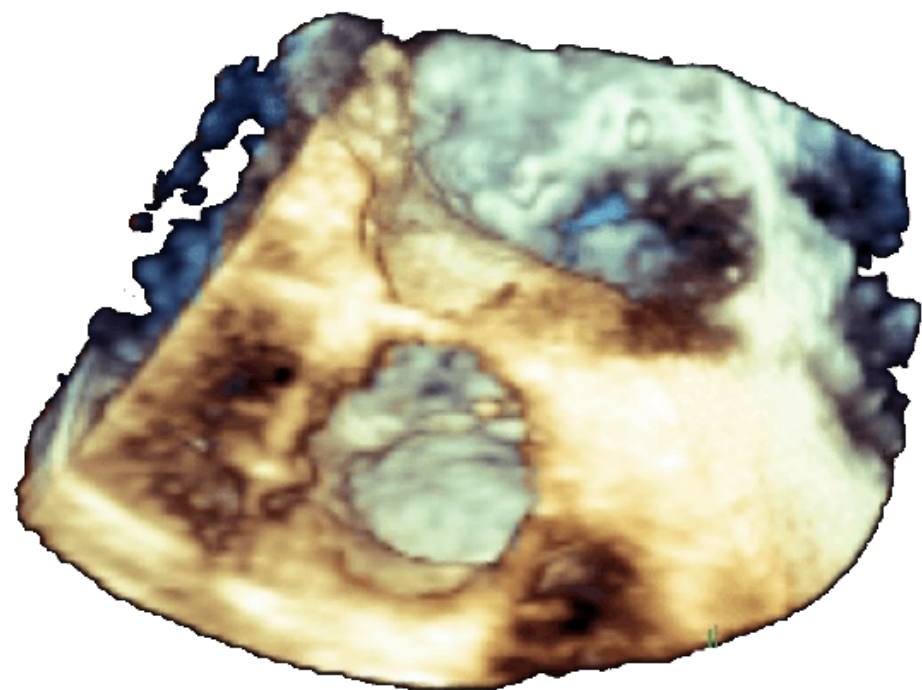


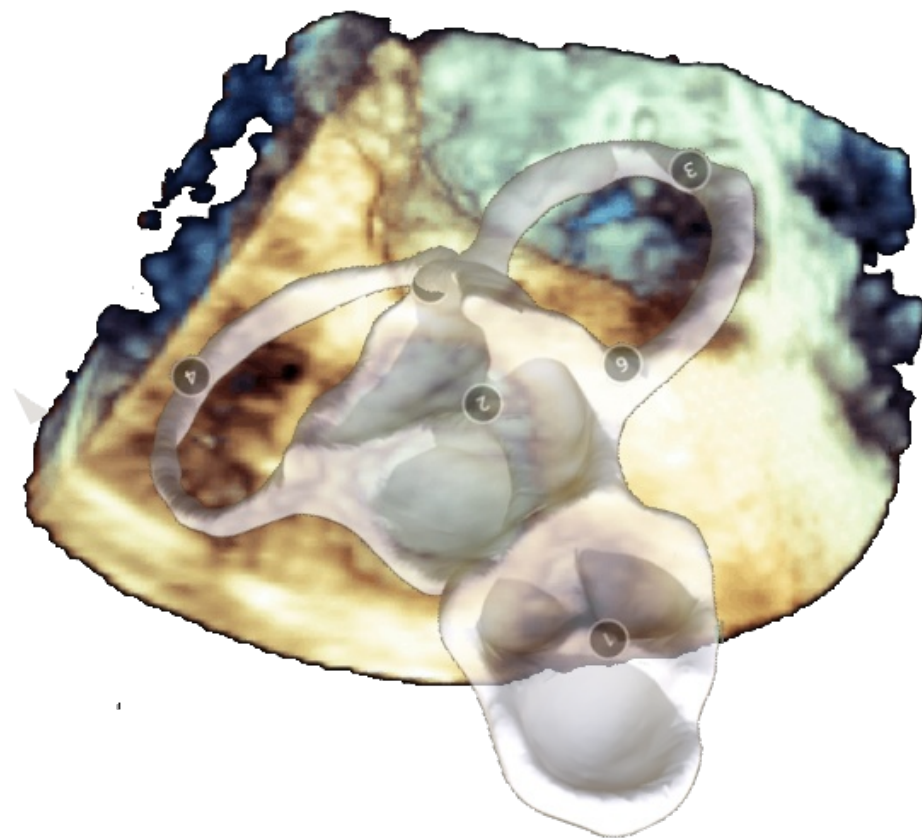
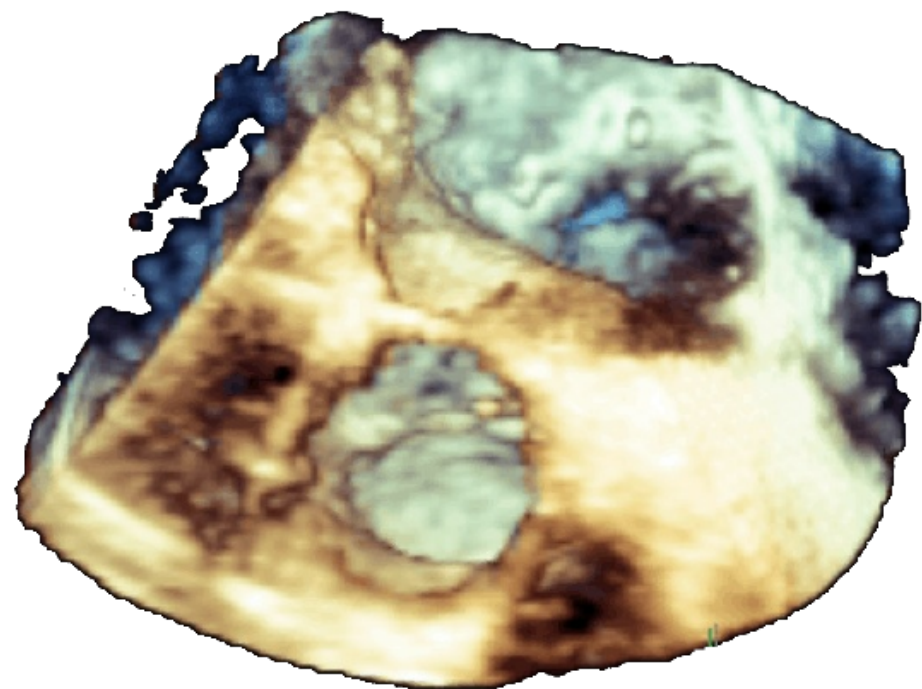


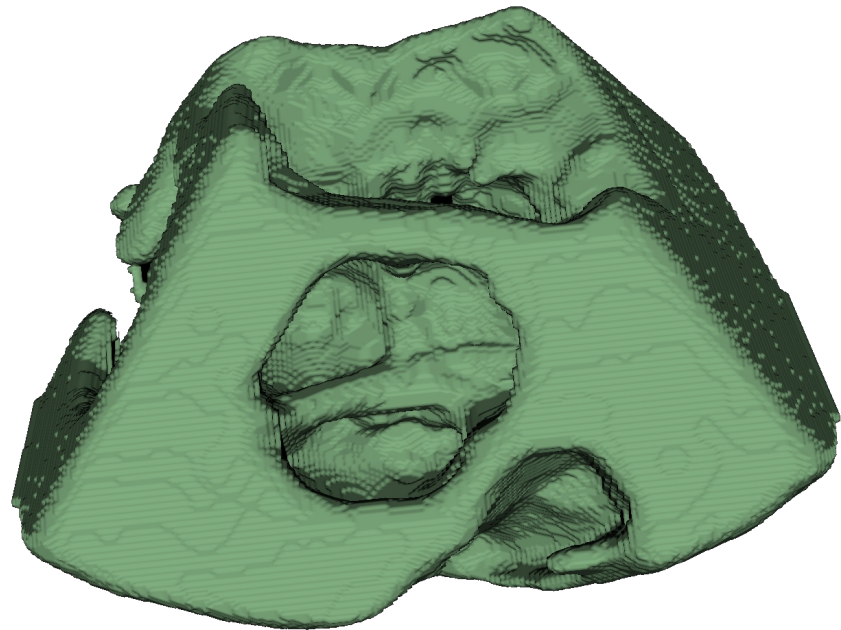


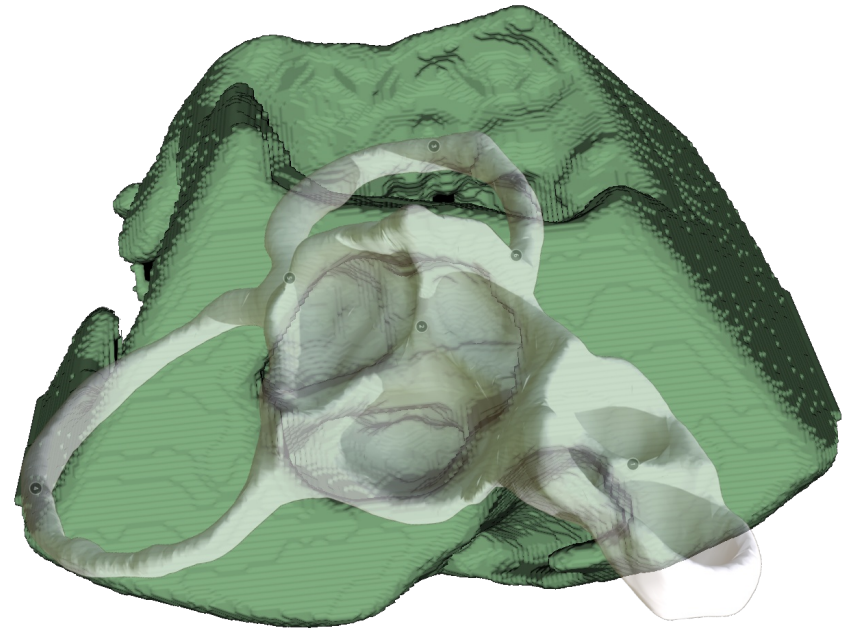
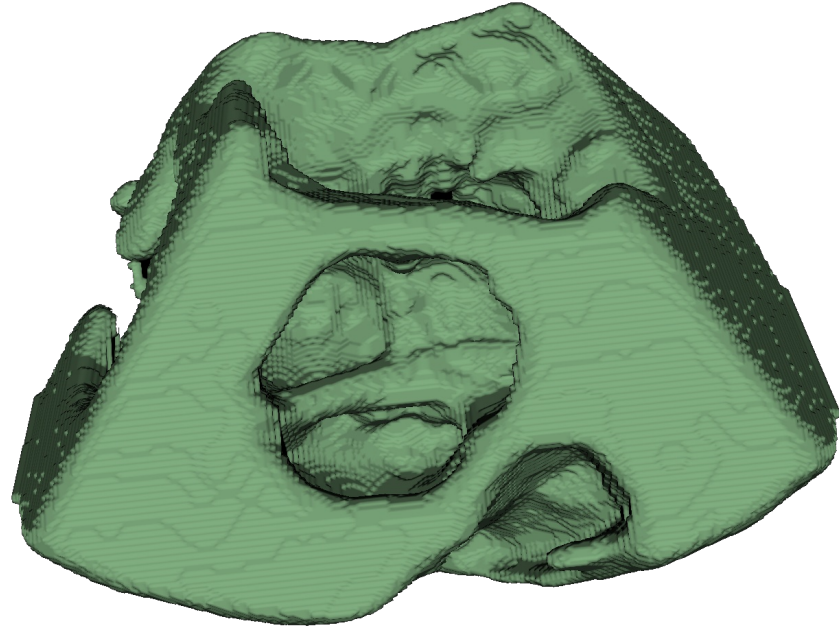










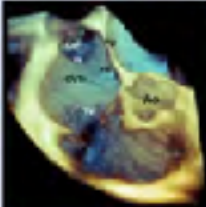
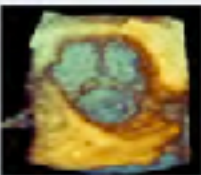


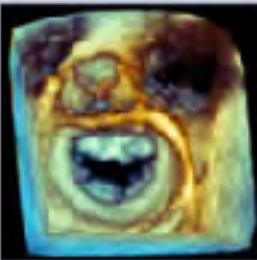
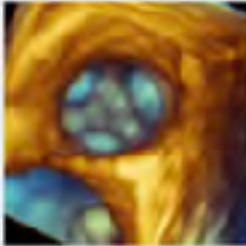





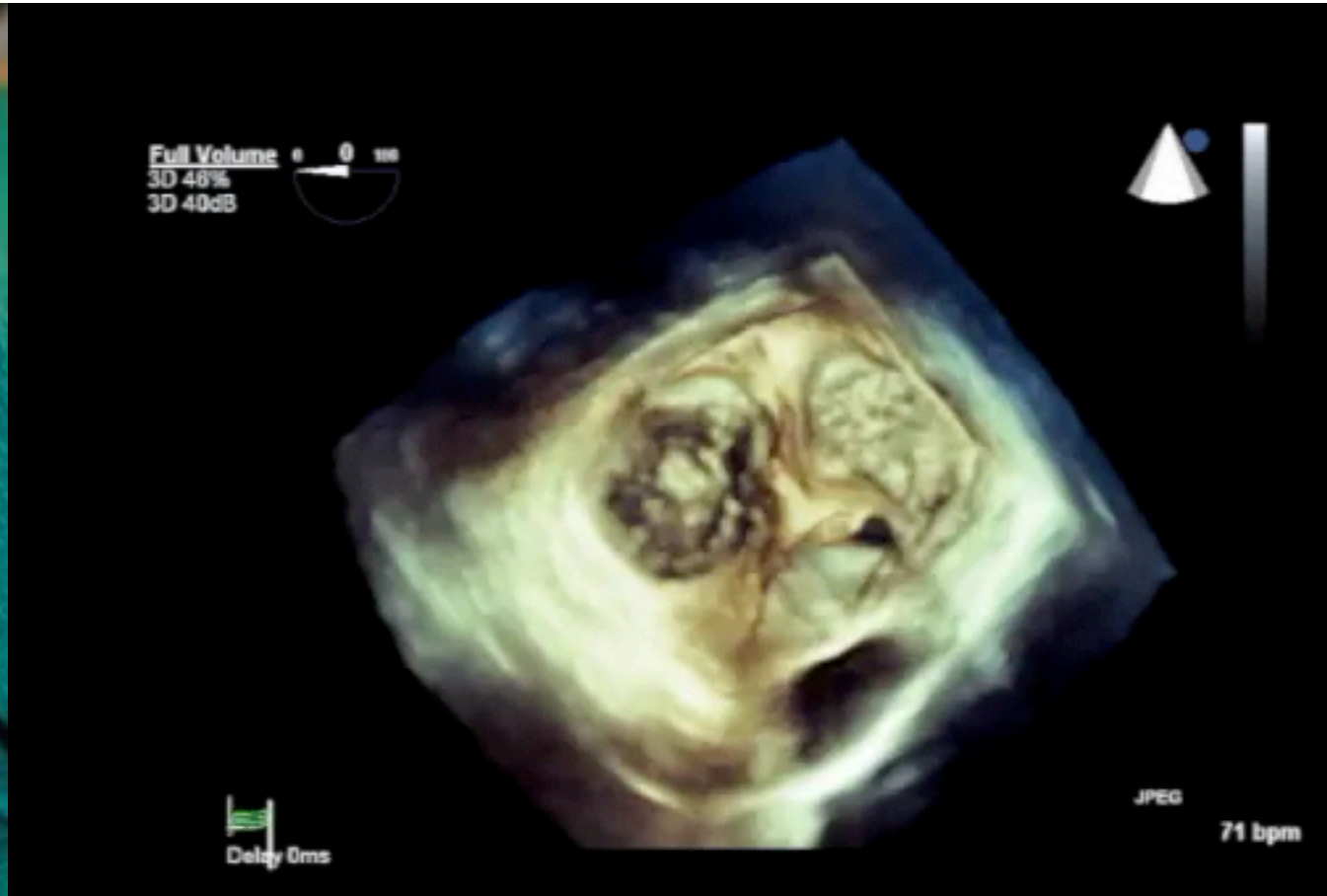
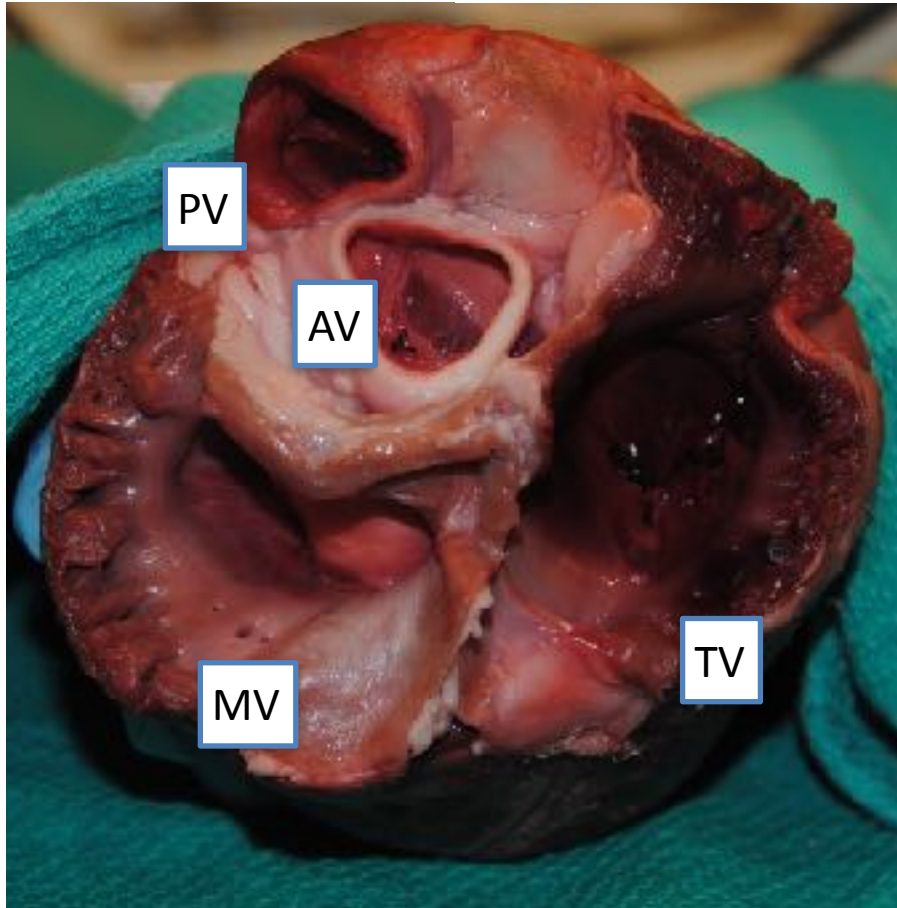


## Guidelines for Performing a Comprehensive Transesophageal Echocardiographic Examination: Recommendations from the American Society of Echocardiography and the Society of Cardiovascular Anesthesiologists

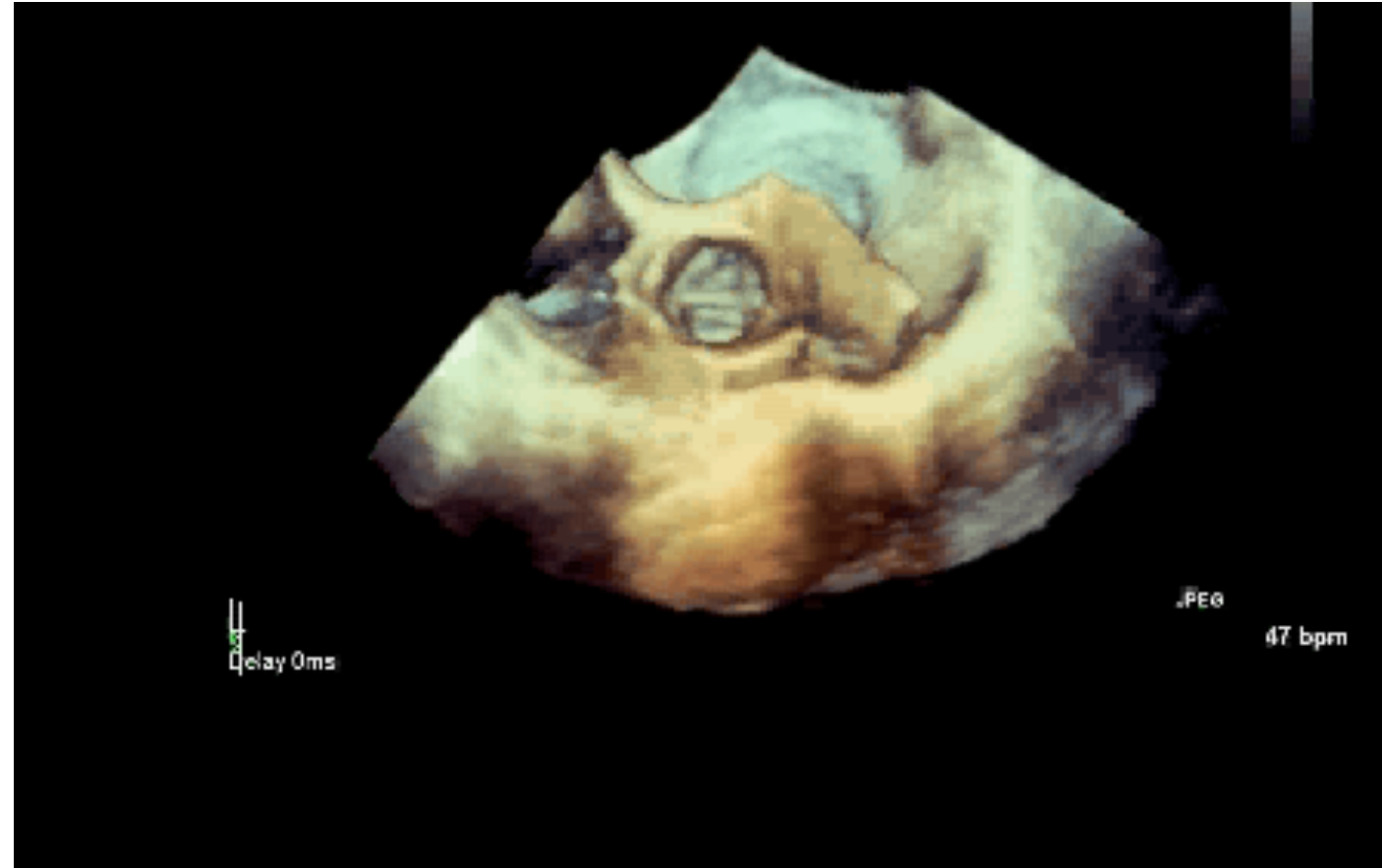
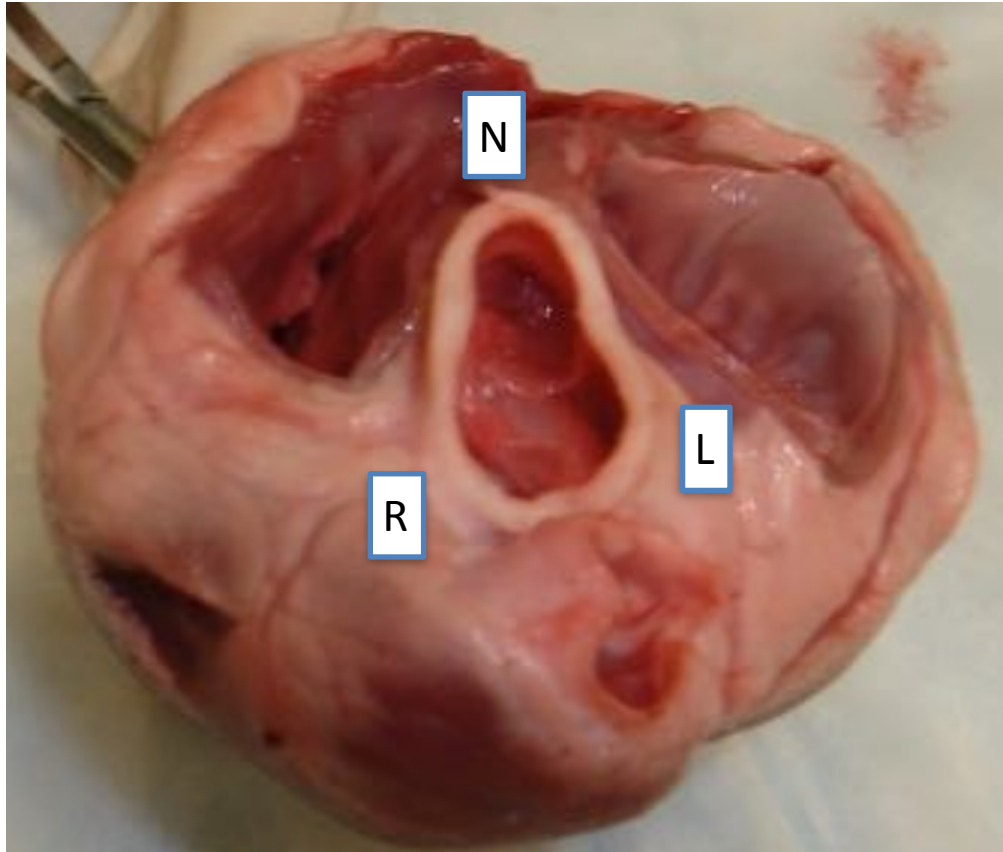
<b>Left Ventricle</b>	<ol style="list-style-type: none"> <li>1. Obtain a view of the left ventricle from the 0°, 60°, or 120° mid-esophageal positions</li> <li>2. Use the biplane mode to check that the left ventricle is centered in a second view 90° to the original.</li> <li>3. Acquire using wide-angle, multi-beat mode</li> </ol>	
<b>Right Ventricle</b>	<ol style="list-style-type: none"> <li>1. Obtain a view of the right ventricle from the 0° mid-esophageal position with the right ventricle tilted so that it is in the center of the image</li> <li>2. Acquire using wide-angle, multi-beat mode</li> </ol>	
<b>Interatrial Septum</b>	<ol style="list-style-type: none"> <li>1. 0° with the probe rotated to the inter-atrial septum</li> <li>2. Acquire using narrow-angle, single-beat or wide-angle, multi-beat modes</li> </ol>	
<b>Aortic Valve</b>	<ol style="list-style-type: none"> <li>1. Obtain a view of the aortic valve from either the 60° mid-esophageal, short-axis view or the 120° mid-esophageal, long-axis view</li> <li>2. Acquire using either the narrow-angle, single-beat or the wide-angle, multi-beat modes</li> </ol>	

<b>Mitral Valve</b>	<ol style="list-style-type: none"> <li>1. Obtain a view of the mitral valve from the 0°, 60°, 90° or 120° mid-esophageal views</li> <li>2. Use the biplane mode to check that the mitral valve annulus is centered with the acquisition plane in a second view 90° to the original.</li> <li>3. Acquire using narrow-angle, single-beat mode</li> </ol>	
<b>Pulmonic Valve</b>	<ol style="list-style-type: none"> <li>1. Obtain a view of the pulmonic valve from either the 90° high-esophageal view or the 120° mid-esophageal, 3-chamber view rotated to center the pulmonic valve</li> <li>2. Acquire using narrow-angle, single-beat mode</li> </ol>	
<b>Tricuspid Valve</b>	<ol style="list-style-type: none"> <li>1. Obtain a view of the tricuspid valve from either the 0° to 30° mid-esophageal, 4-chamber view tilted so that the valve is centered in the imaging plane or the 40° transgastric view with antelexion</li> <li>2. Acquire using a narrow-angle, single-beat mode</li> </ol>	

# Heart Base

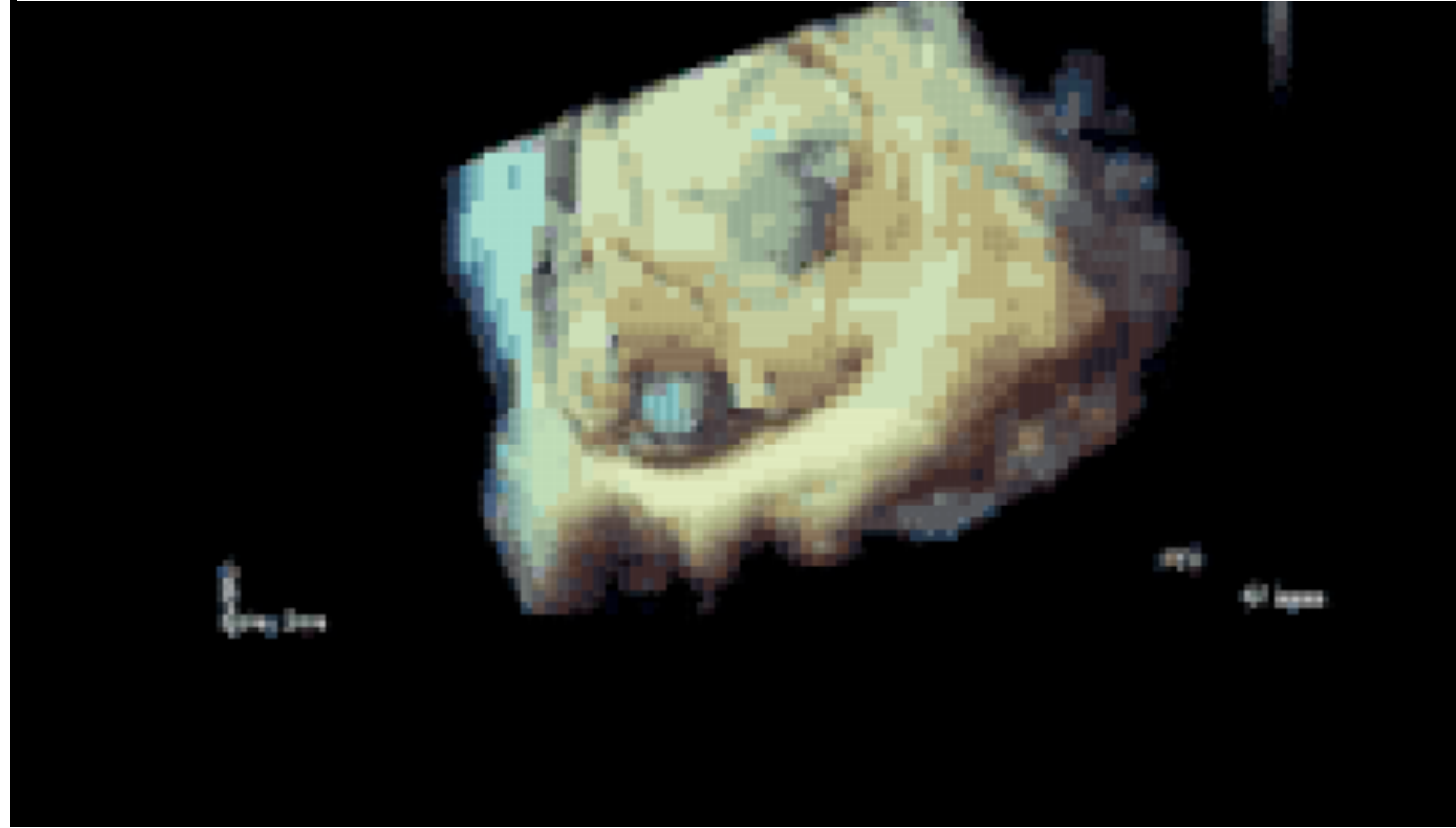
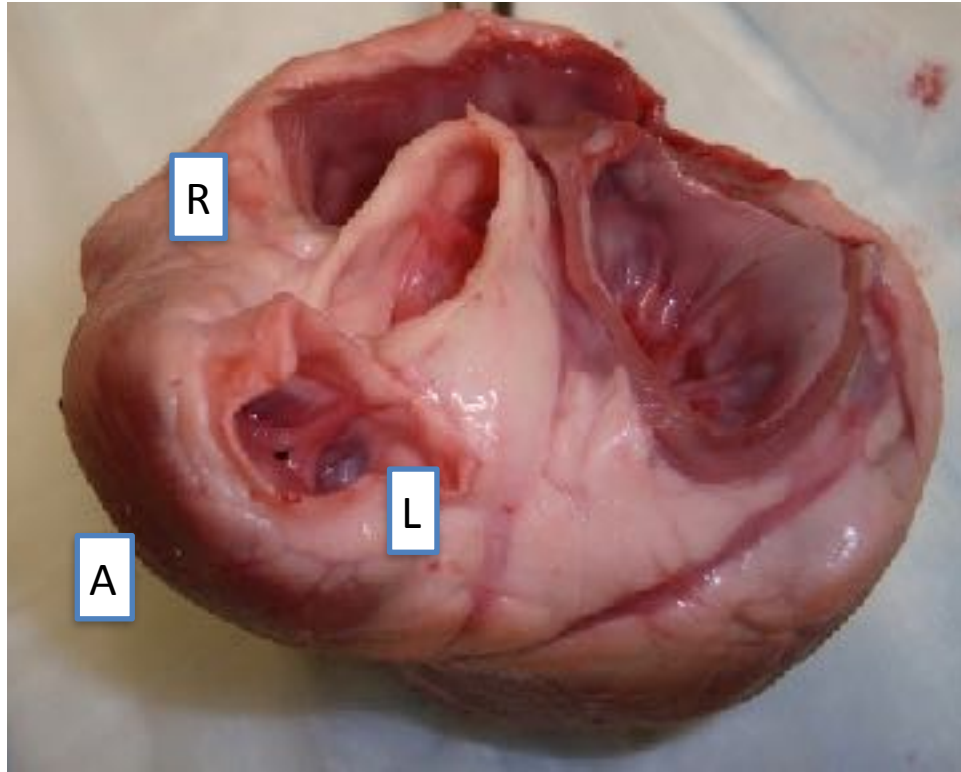


# AV

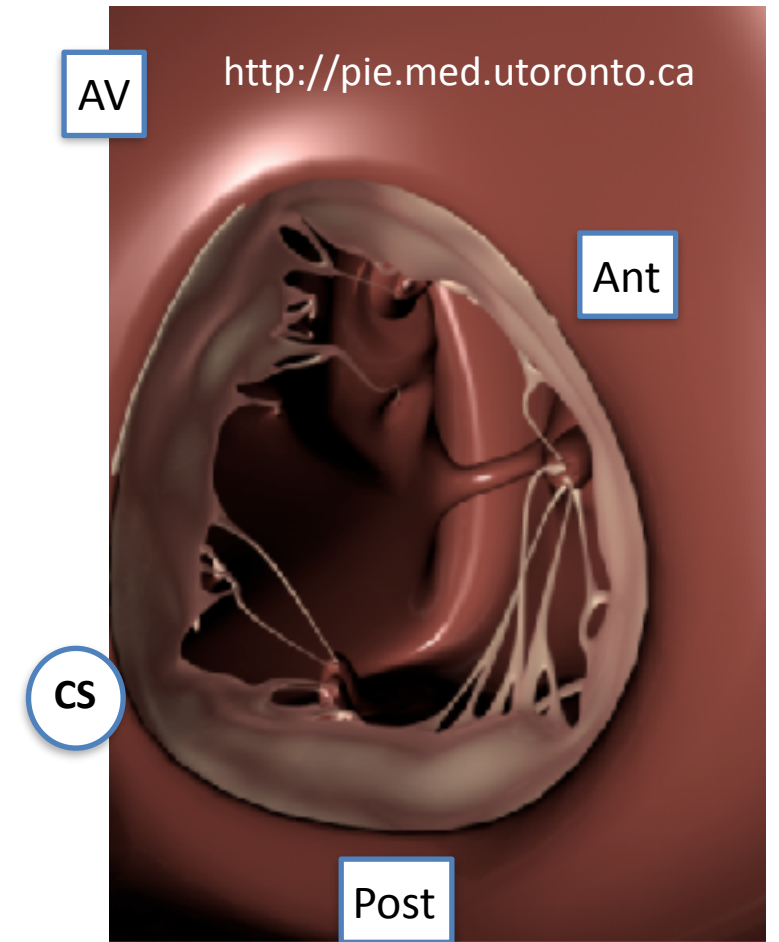
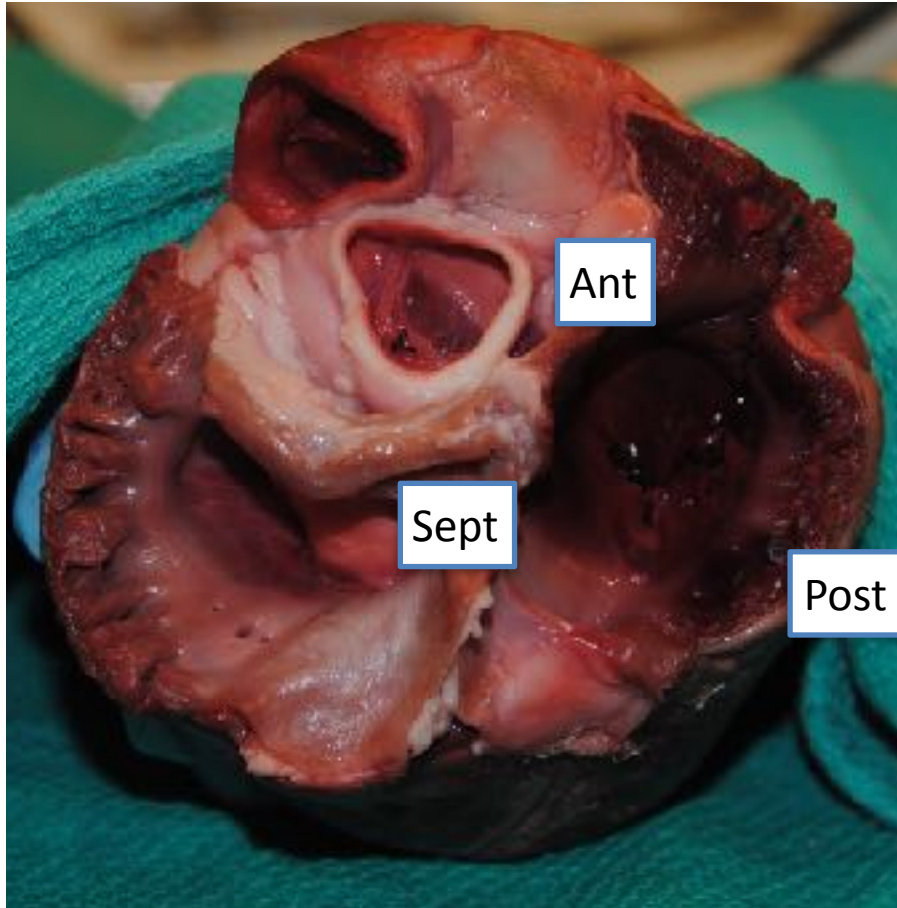




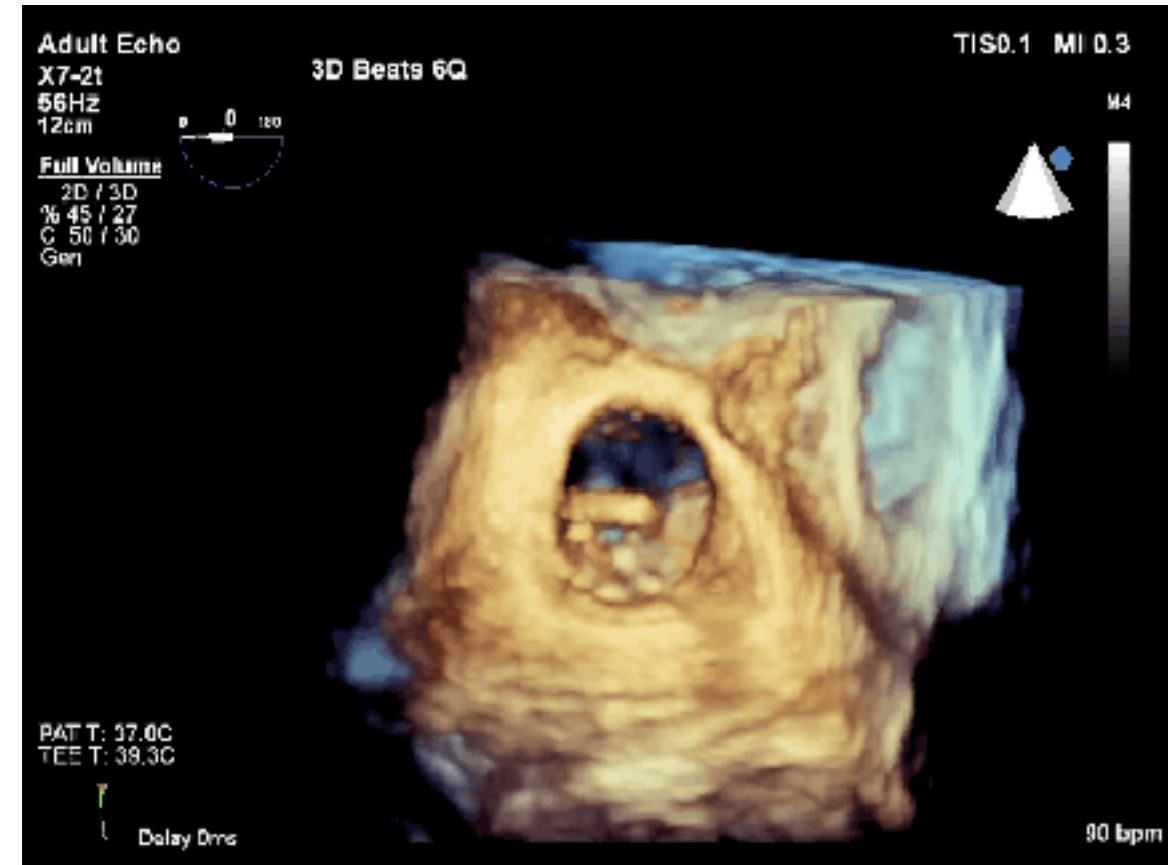
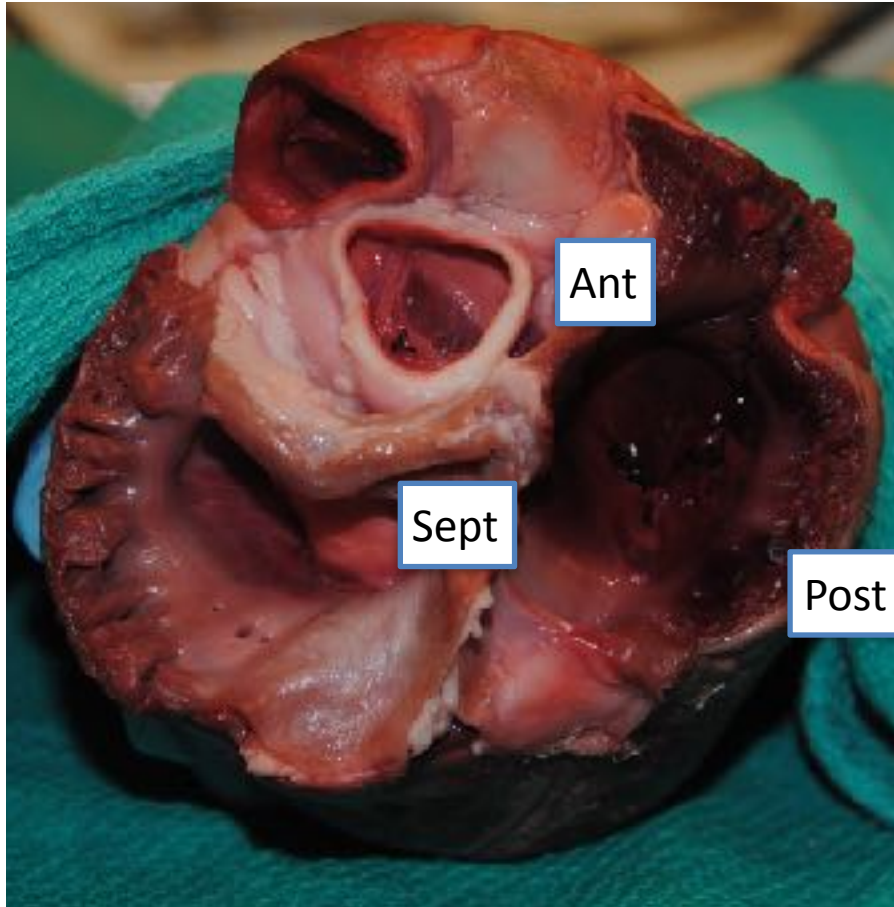
# PV



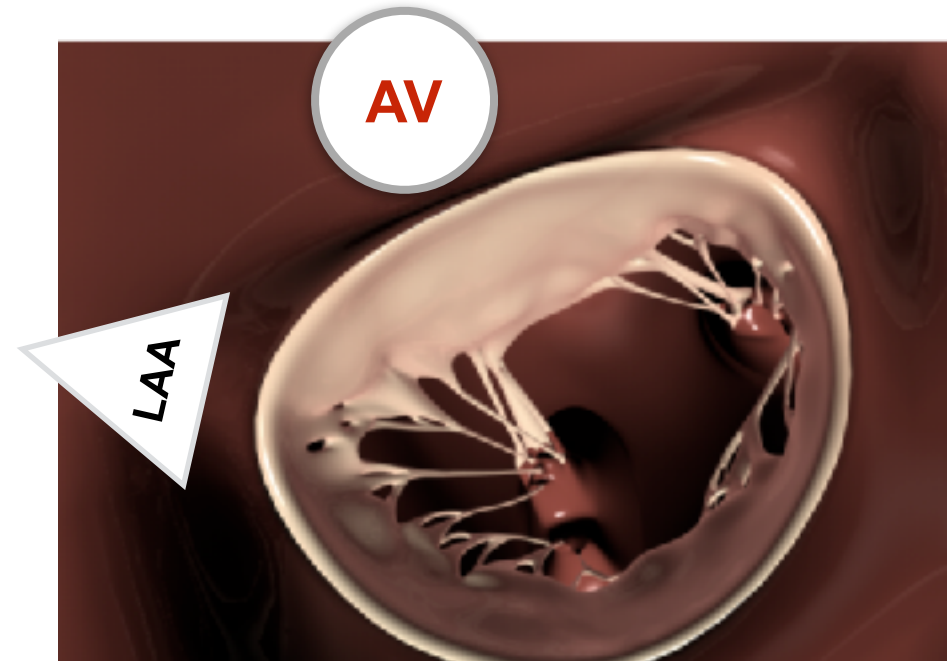
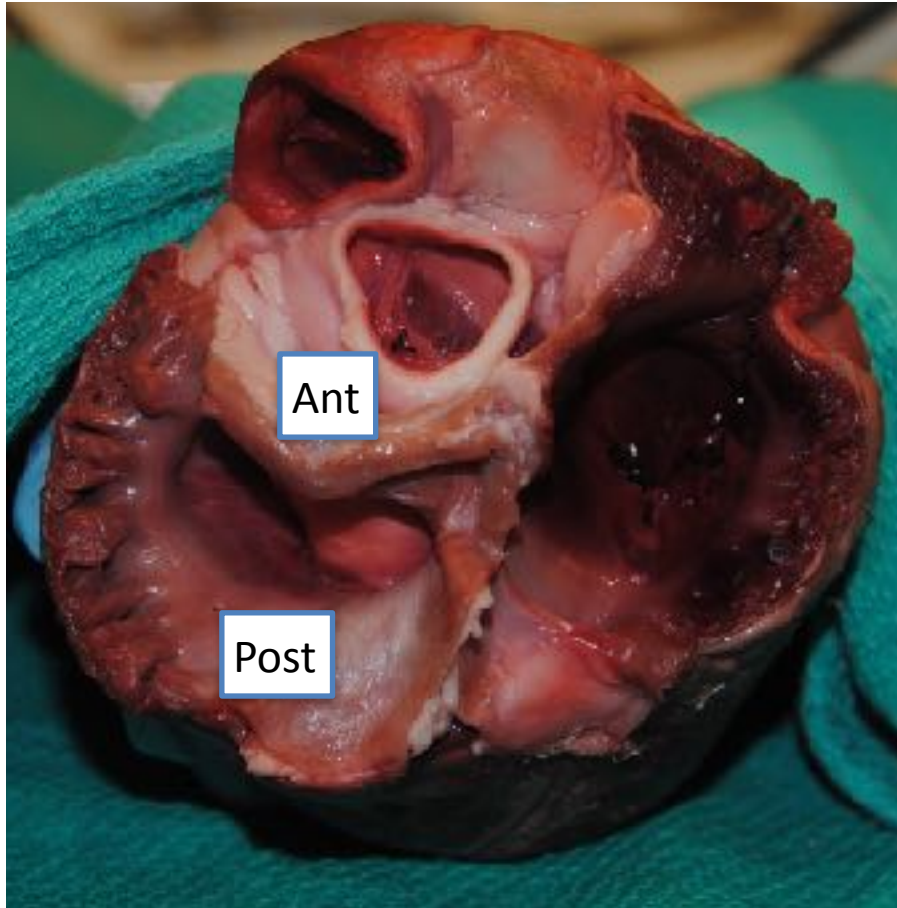
# TV



# TV



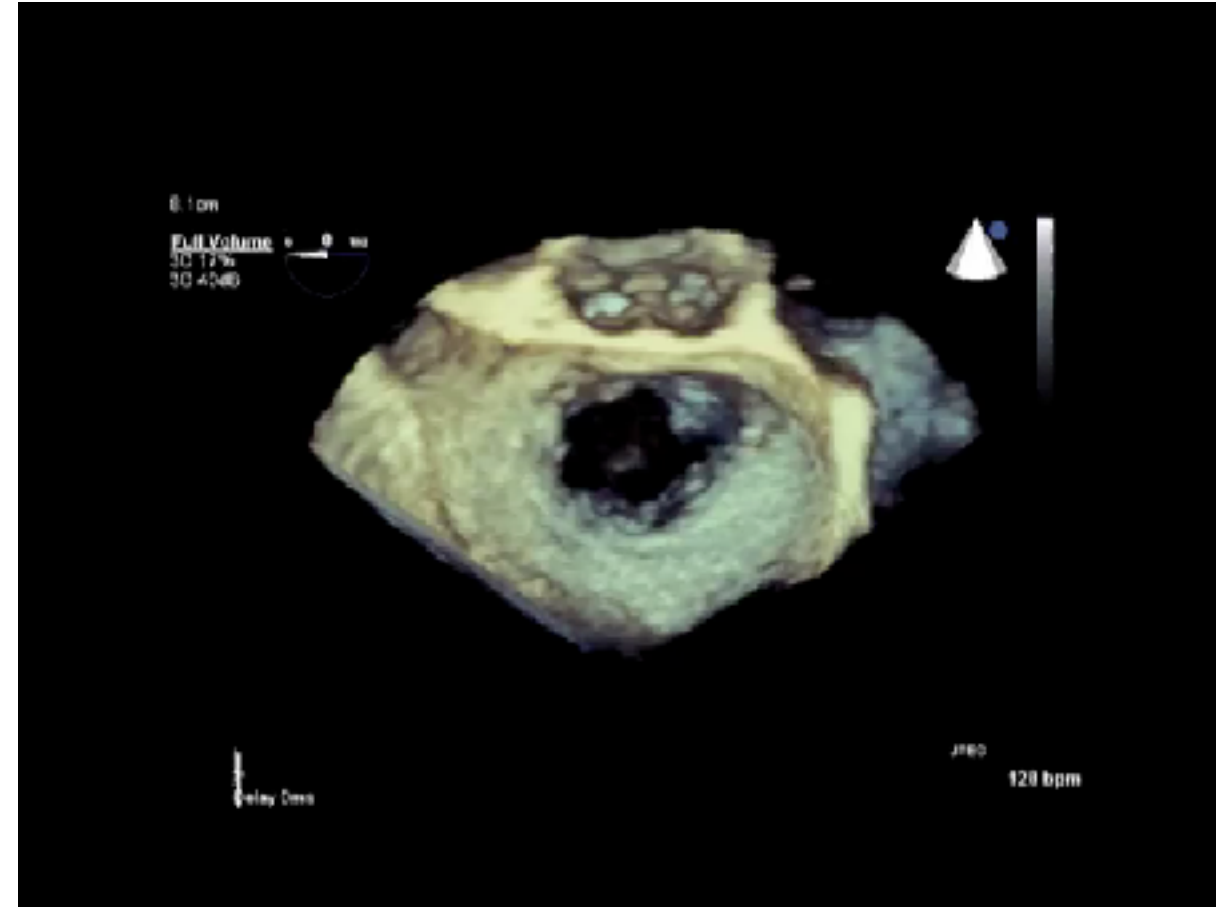
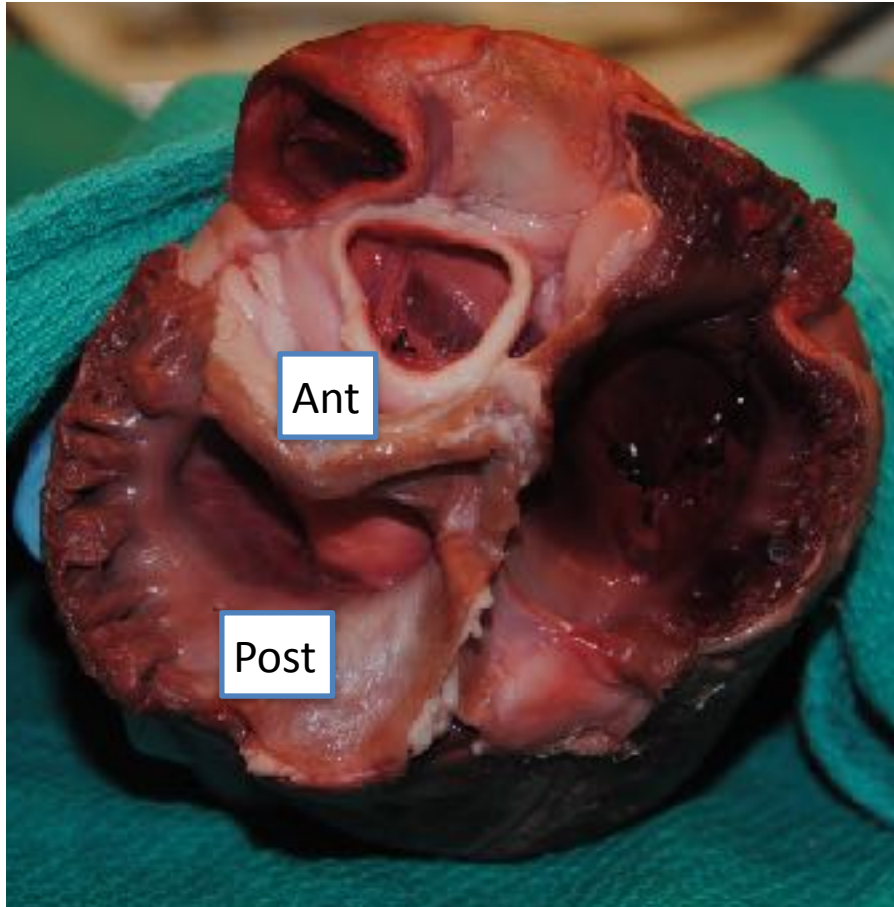
# TV



[pie.med.utoronto.ca](http://pie.med.utoronto.ca)



# TV



# Thank you Very much

Massimiliano.Meineri@medizin.uni-Leipzig.de

