



UNIVERSITY OF OTTAWA
HEART INSTITUTE

INSTITUT DE CARDIOLOGIE
DE L'UNIVERSITÉ D'OTTAWA

3D TEE for MitraClip® Implantation

Adam Dryden
University of Ottawa Heart Institute
adryden@ottawaheart.ca

Disclosures

- None



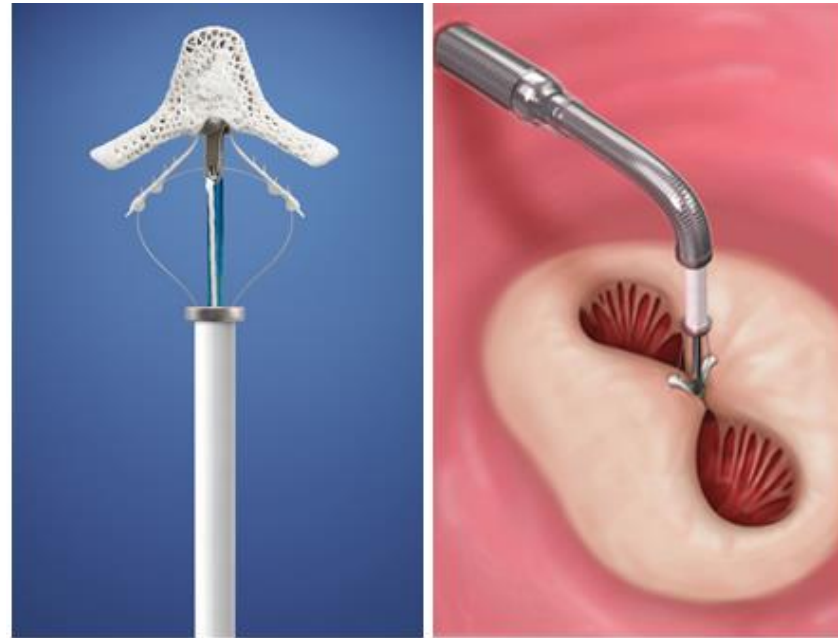
Caveats

- Mitraclips are some of the most fun TEEs & cases that I do
- This is not a “best of the best images” presentation
 - Real images from my last 10 cases
- This talk is derived from our learned experiences at UOHI



MitraClip®

- Device inserted percutaneously via femoral vein across the intra-atrial septum
- Replicates an edge-to-edge repair for the Mitral Valve
- Third generation device (XTR) approved by FDA
- Abbot




MitraClip Monograph

- Degenerative MR with comorbidities precluding surgical intervention
- Anatomic Considerations
 - The primary regurgitant jet is non-commissural. If a secondary jet exists, it must be considered clinically insignificant
 - Mitral valve area $\geq 4.0\text{cm}^2$
 - Minimal calcification in the grasping area
 - No leaflet cleft in the grasping area
 - Flail width $< 15\text{ mm}$ and flail gap $< 10\text{ mm}$



The Past Few Months...



How 3D Images Change What We Do

1. Pre-procedural

- Anatomy, anatomy, anatomy
- Localizing the leak

2. Intra-procedural

- Clip alignment and positioning
- More clips?

3. Post-procedural

- Leak quantification
- Mitral Valve Area



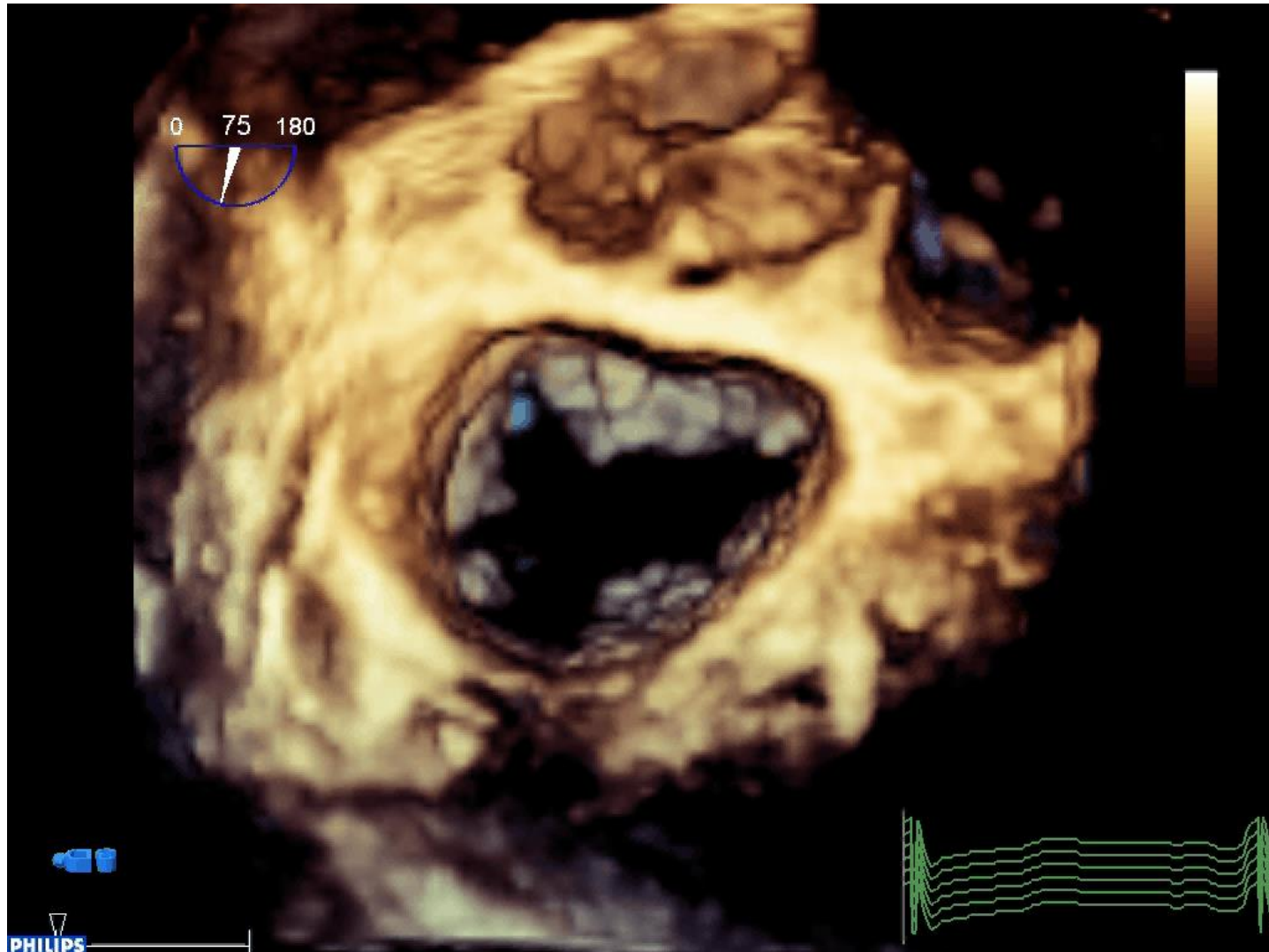
How 3D Images Change What We Do

1. Pre-procedural

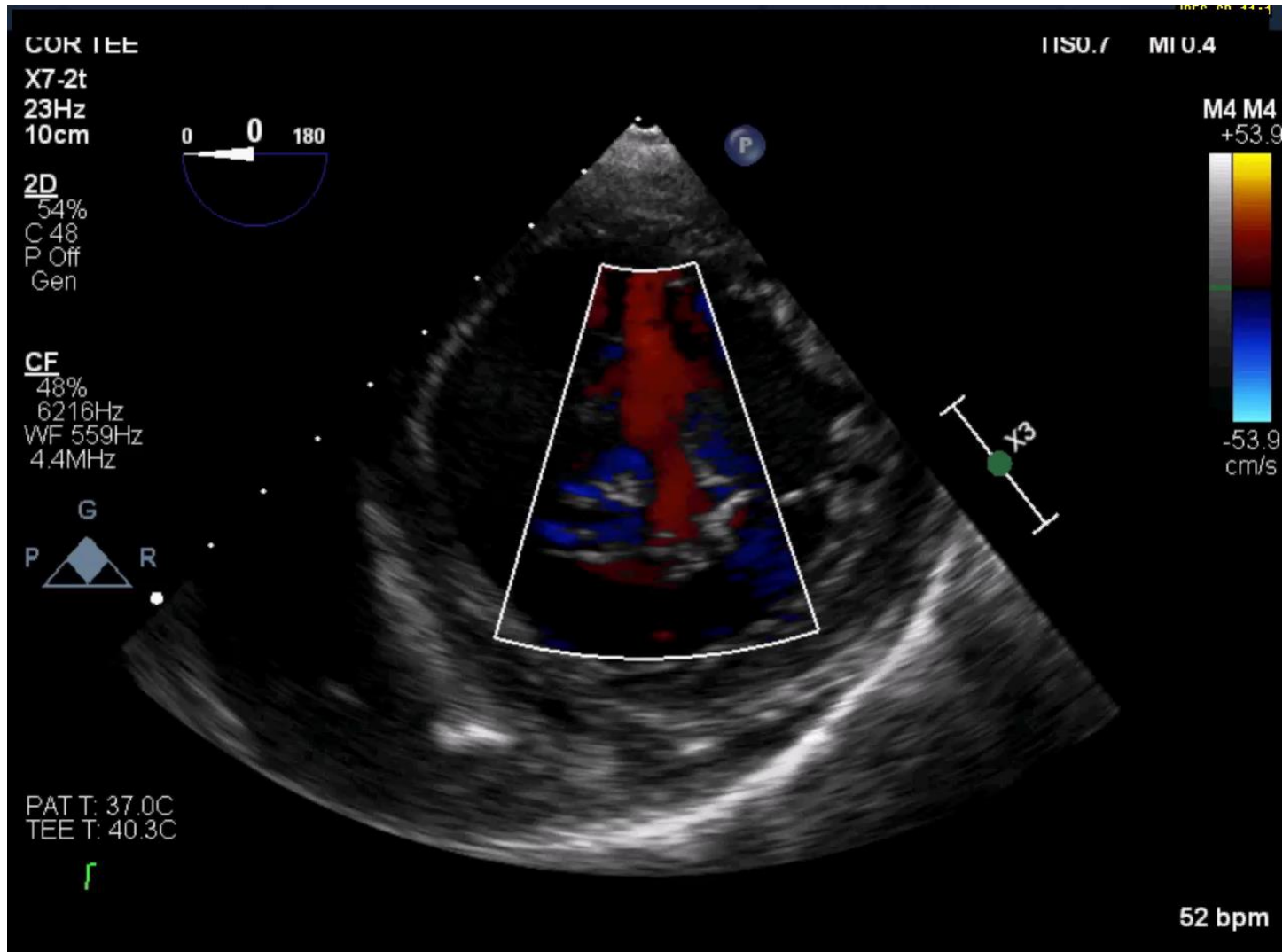
- Anatomy, anatomy, anatomy
 - Nodularity
 - Exaggerated indentations in posterior leaflet
 - Leaflet mobility
 - Mitral Valve Area
- Localizing the leak
 - Which scallop and what part of the scallop
 - How medial/lateral
 - Does it arise from an indentation?
 - Multiple leaks?



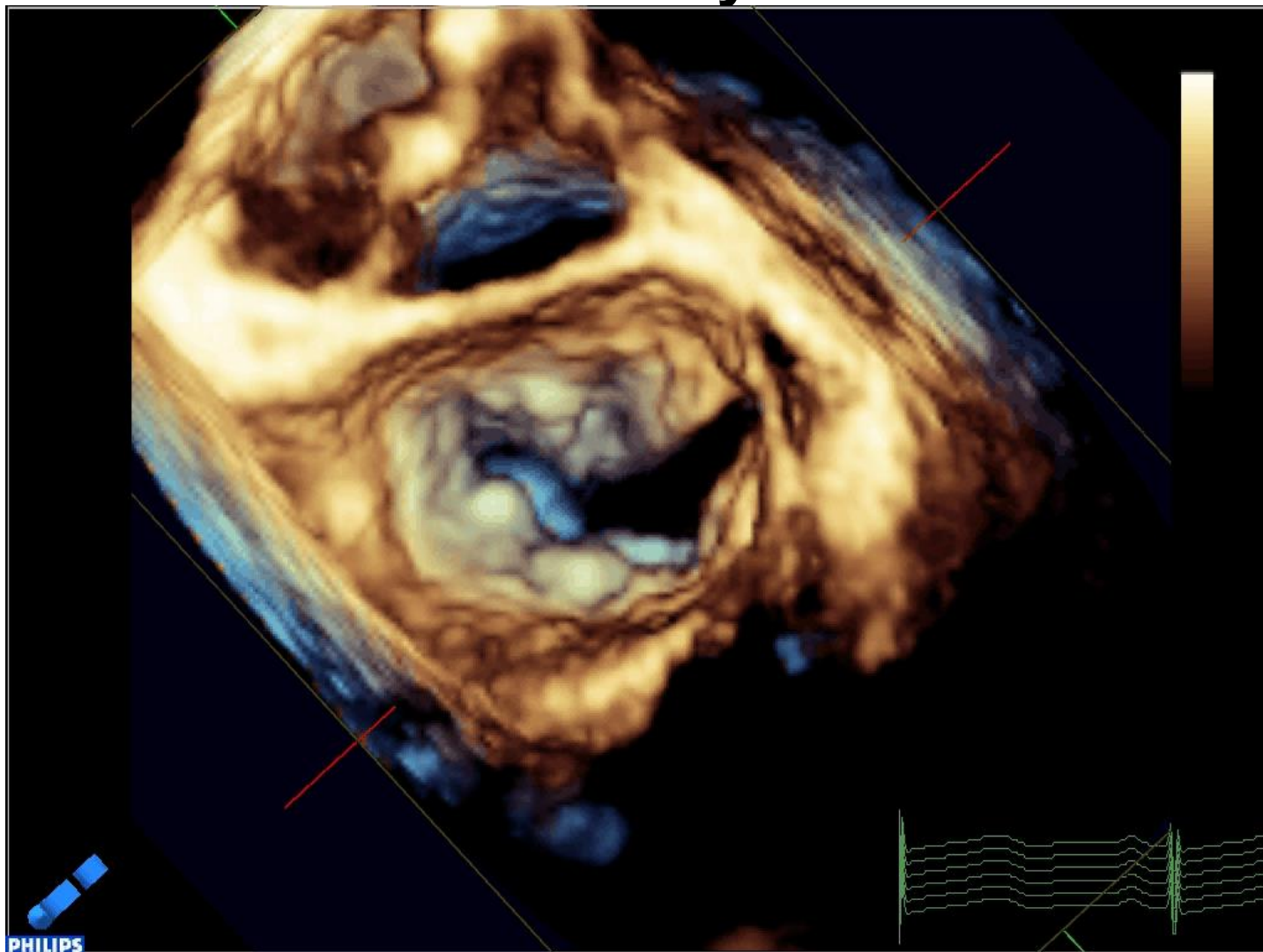
Posterior Leaflet Indentations



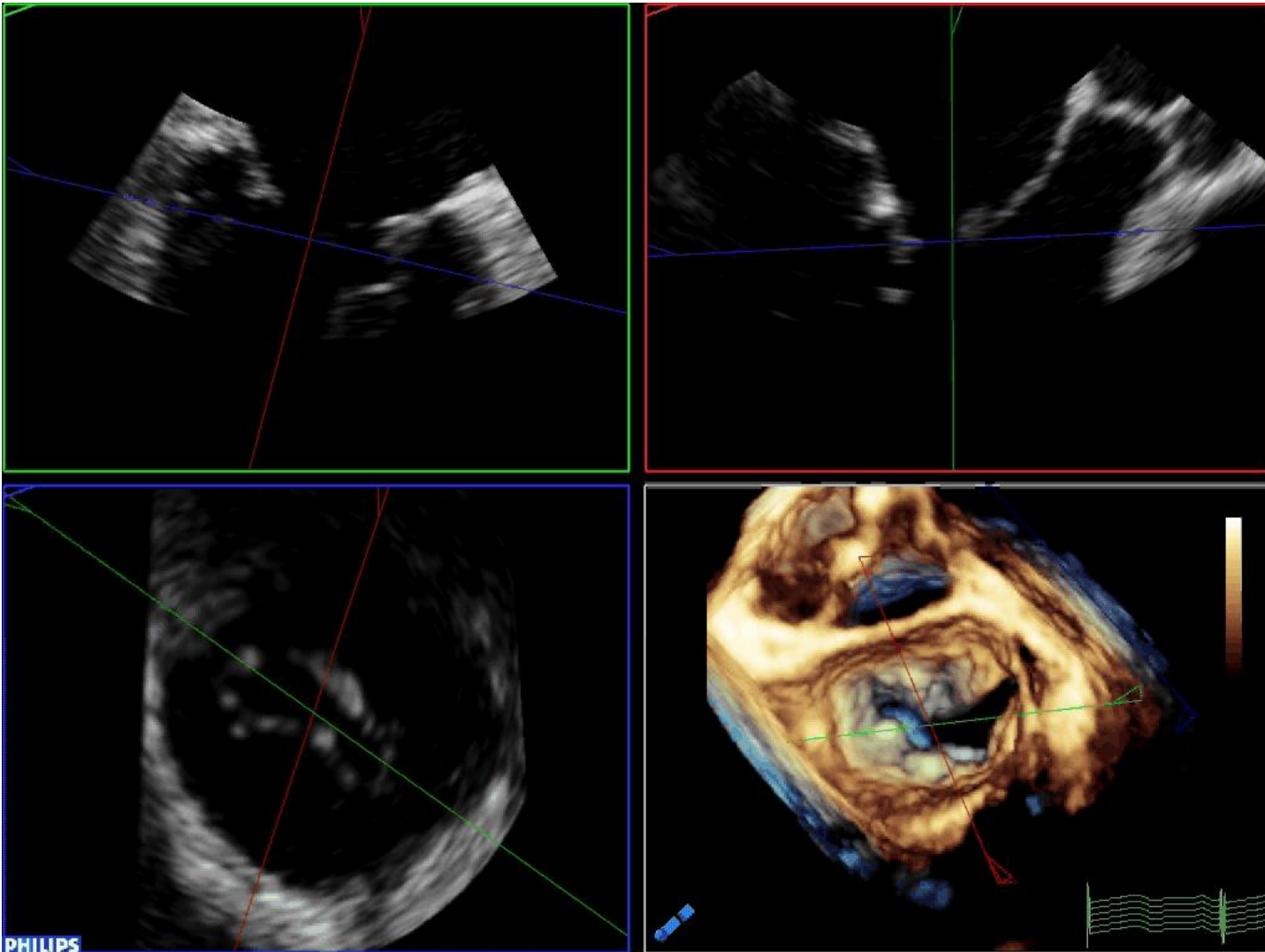
Posterior Leaflet Indentations



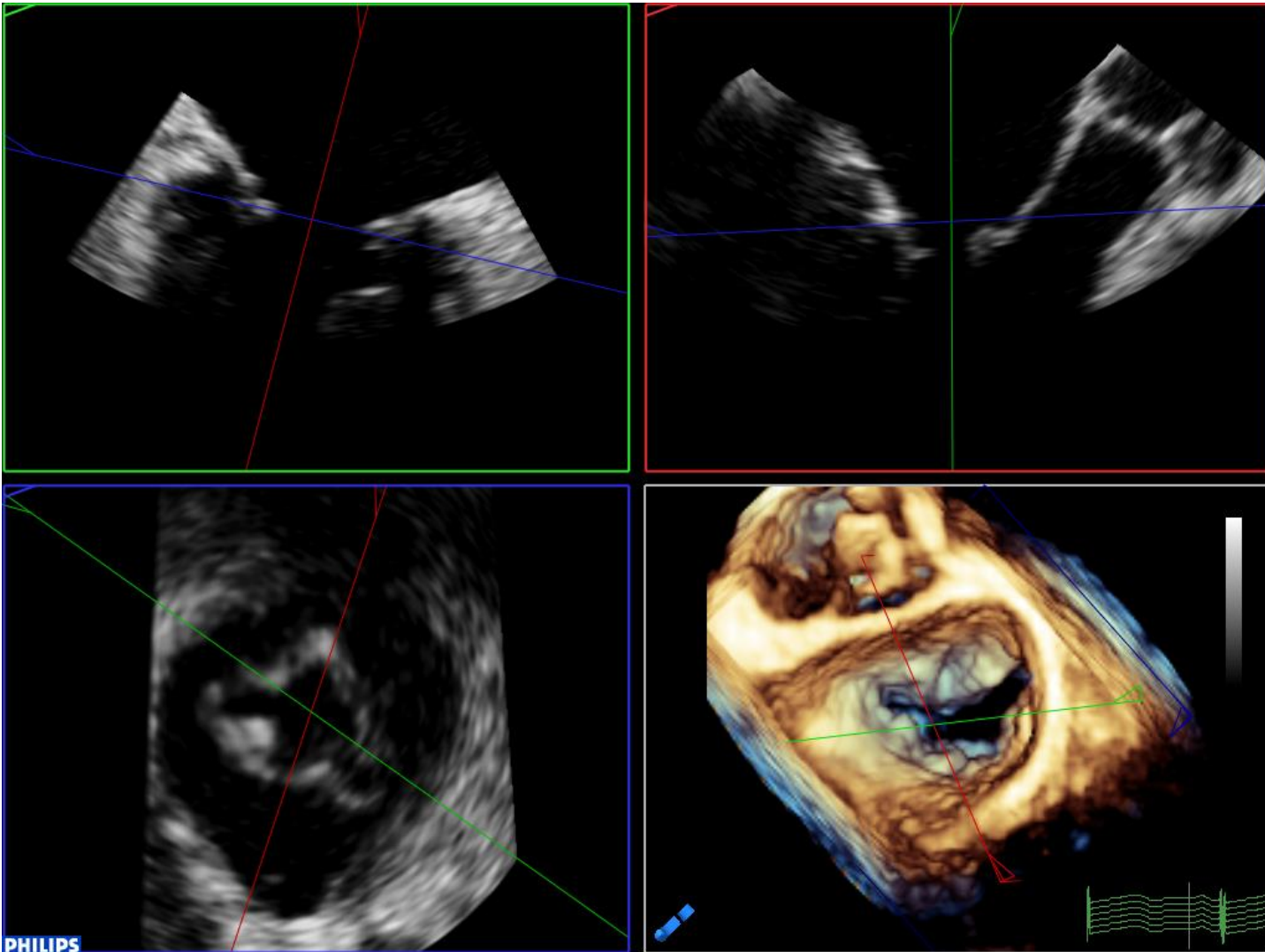
Posterior Leaflet Indentations & Leaflet Mobility



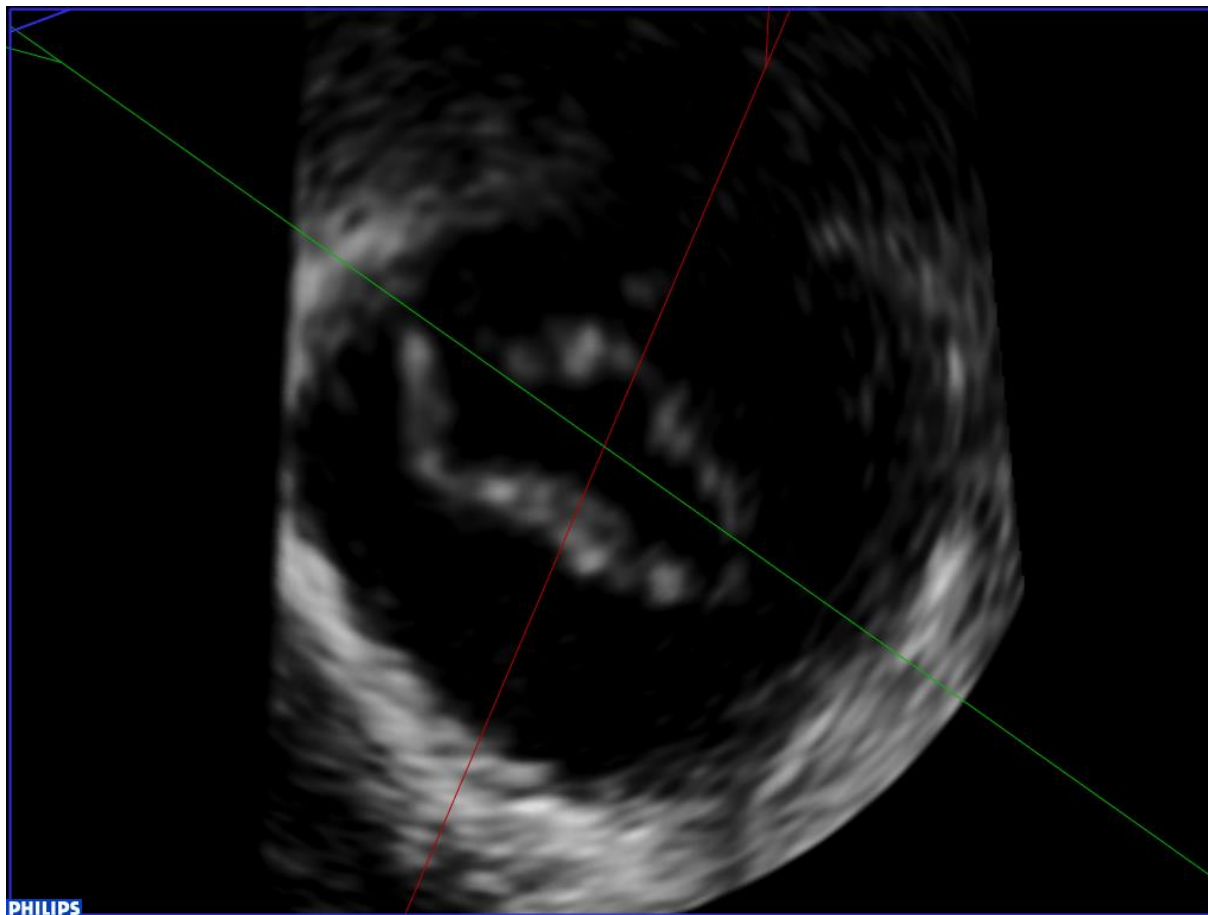
Posterior Leaflet Indentations



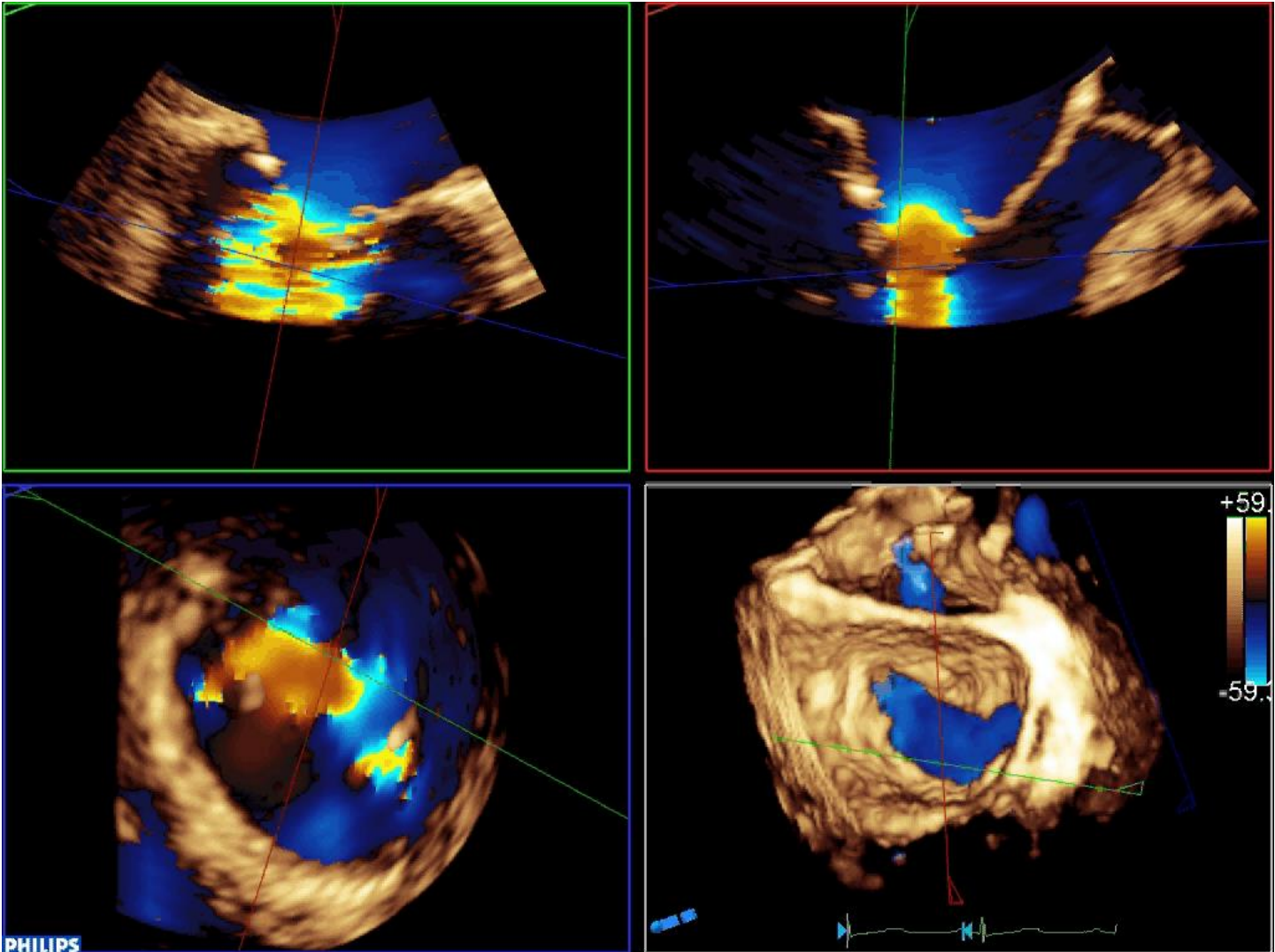
Posterior Leaflet Indentations & Bi-Leaflet Nodules



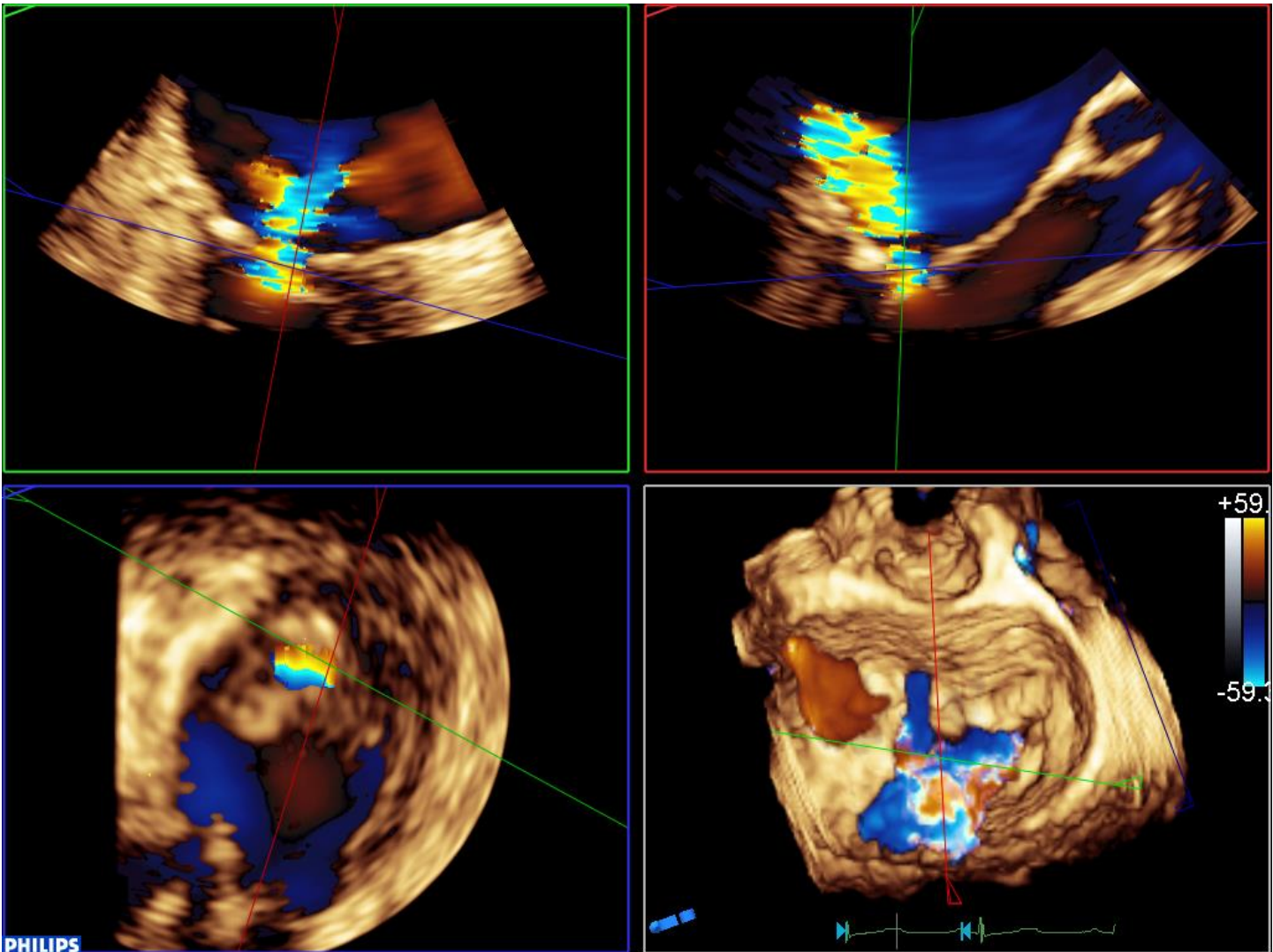
Mitral Valve Area



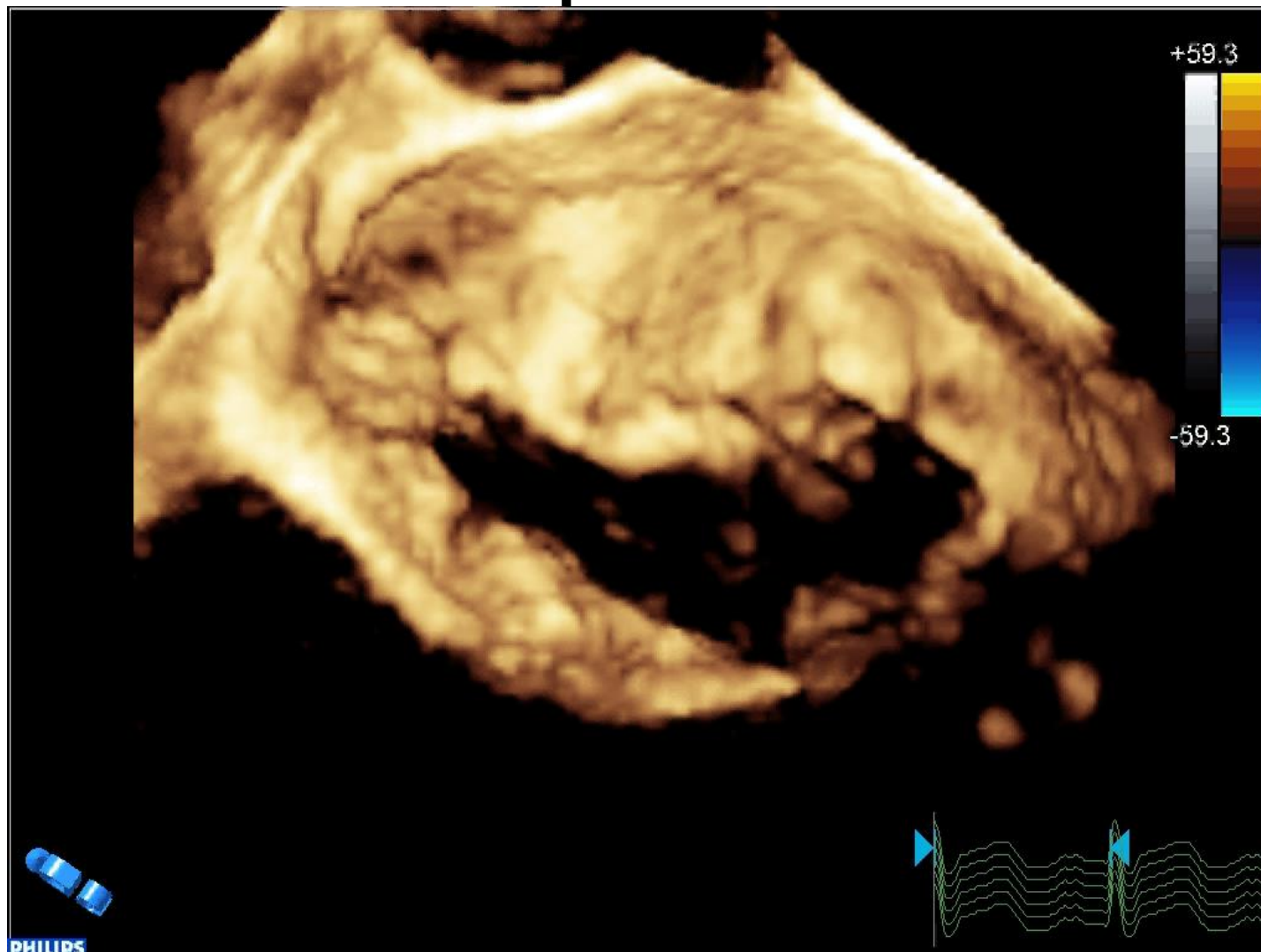
Posterior Leaflet Indentations



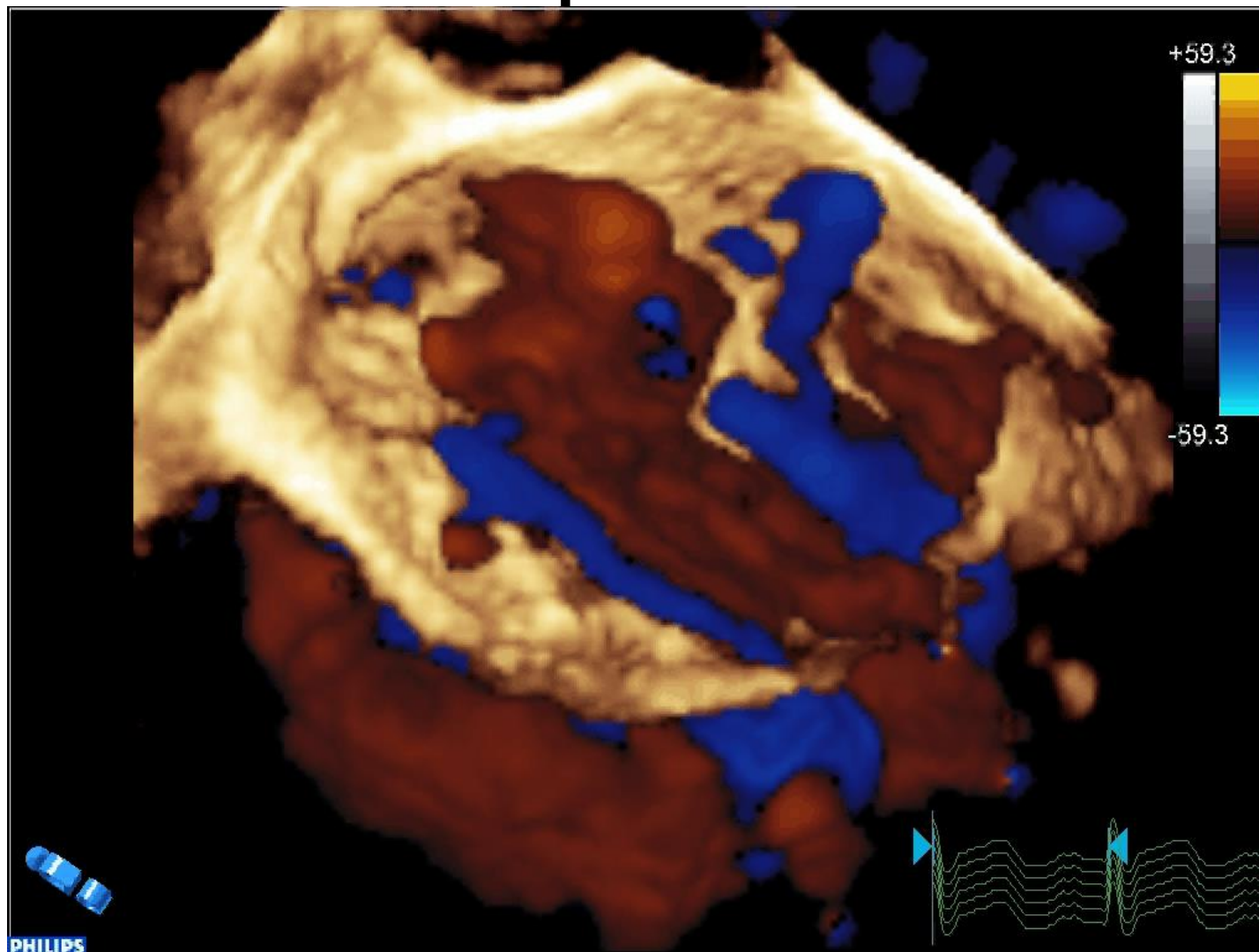
Posterior Leaflet Indentation and Bileaflet Nodules



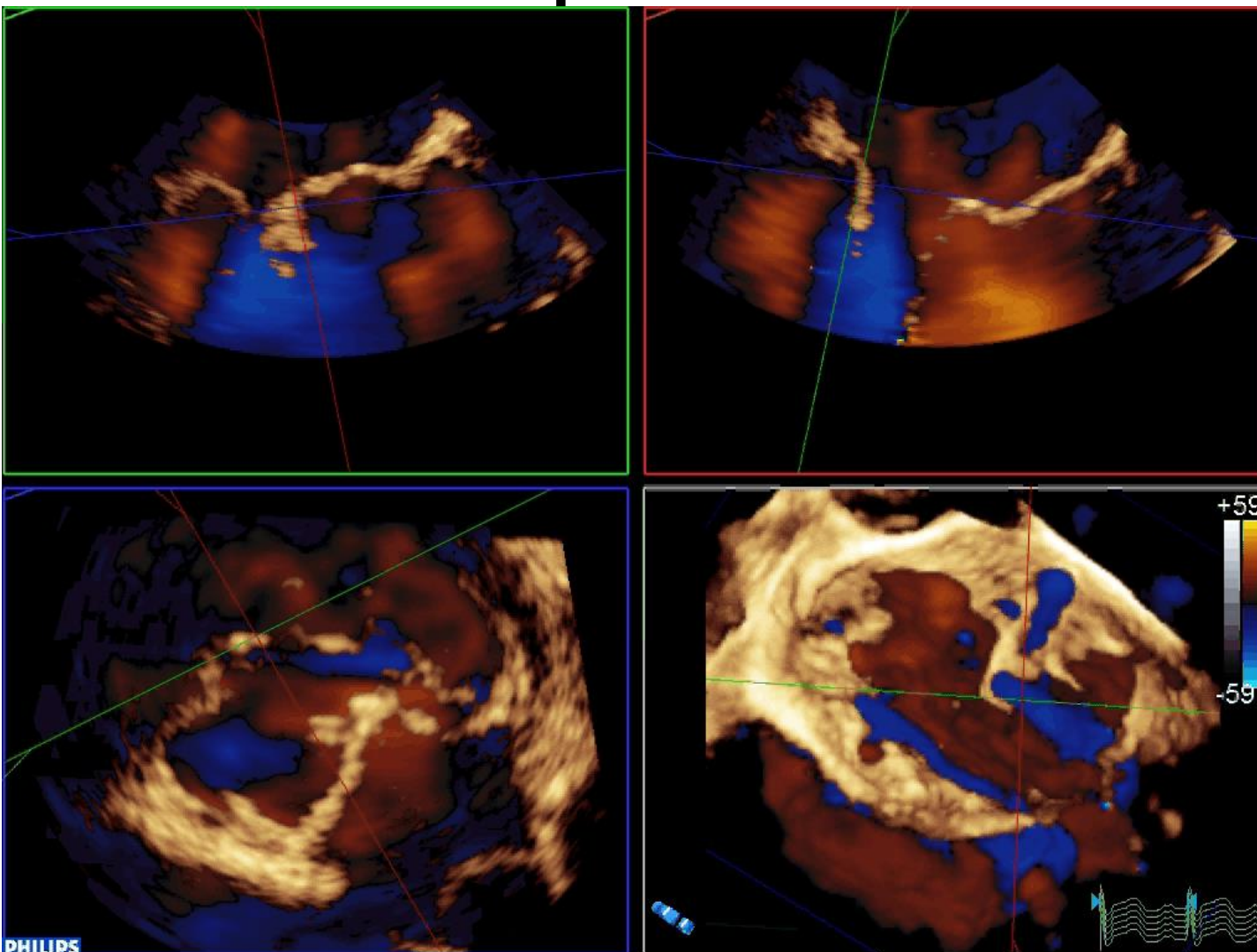
Multiple Leaks



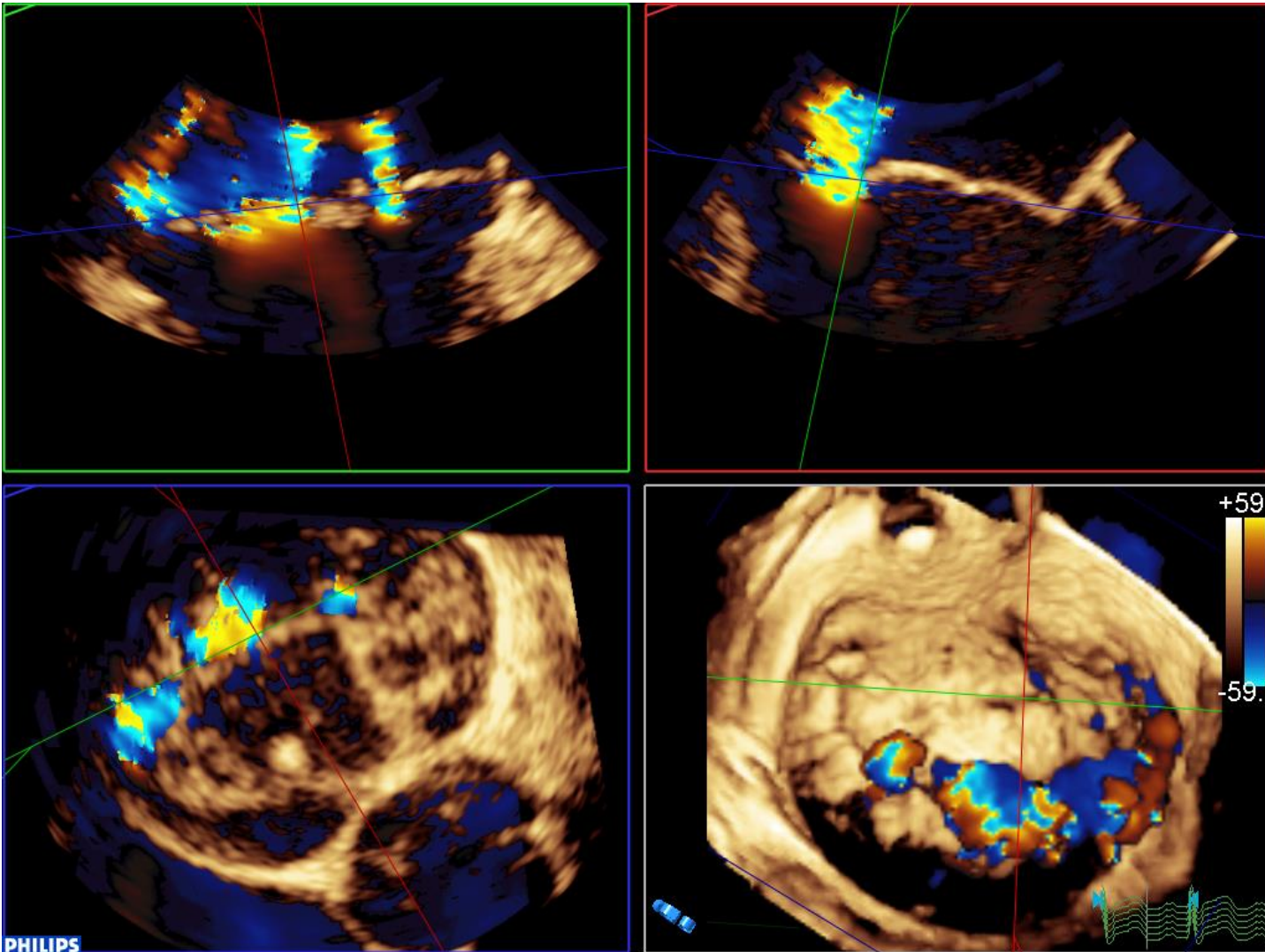
Multiple Leaks



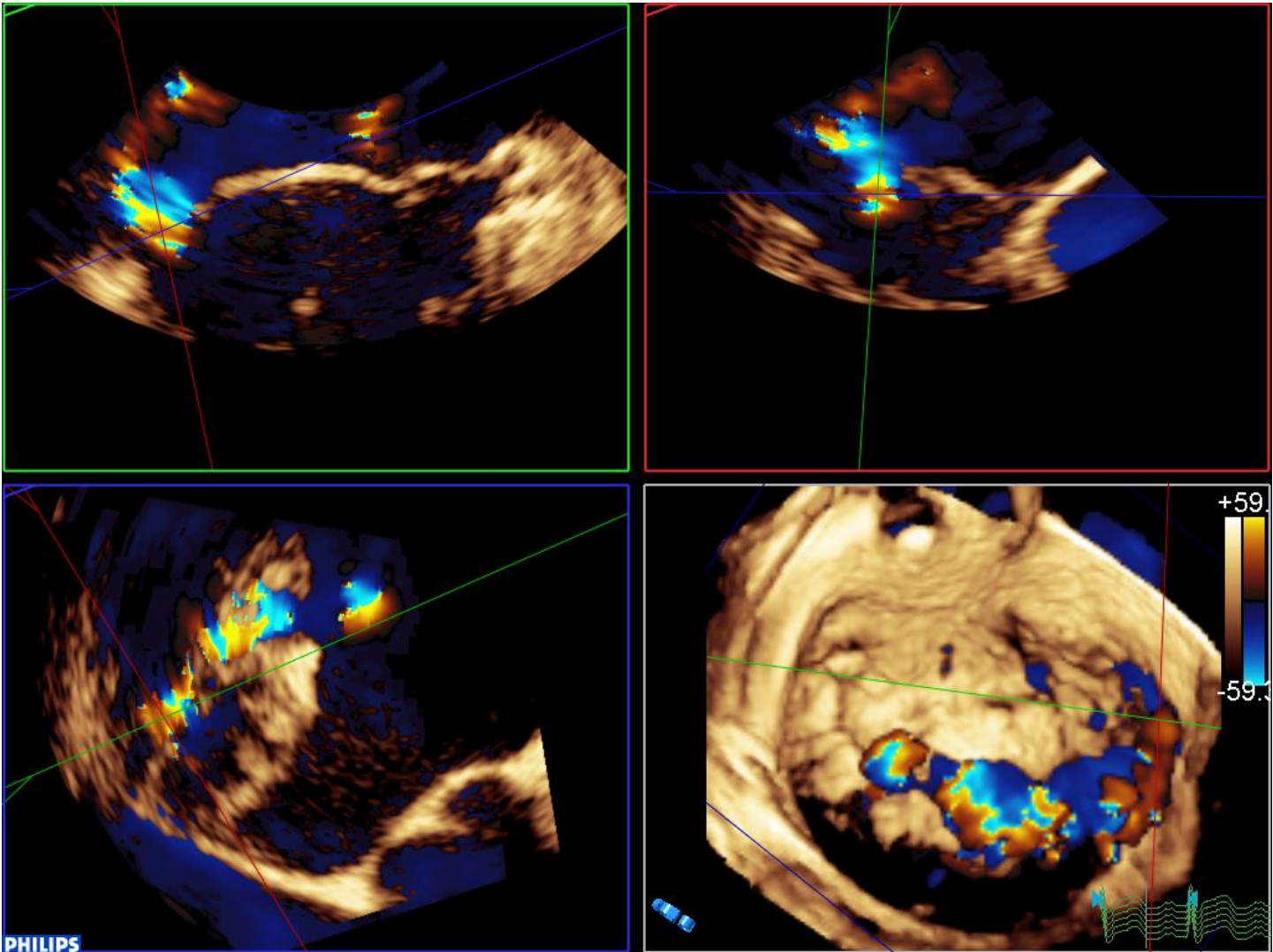
Multiple Leaks



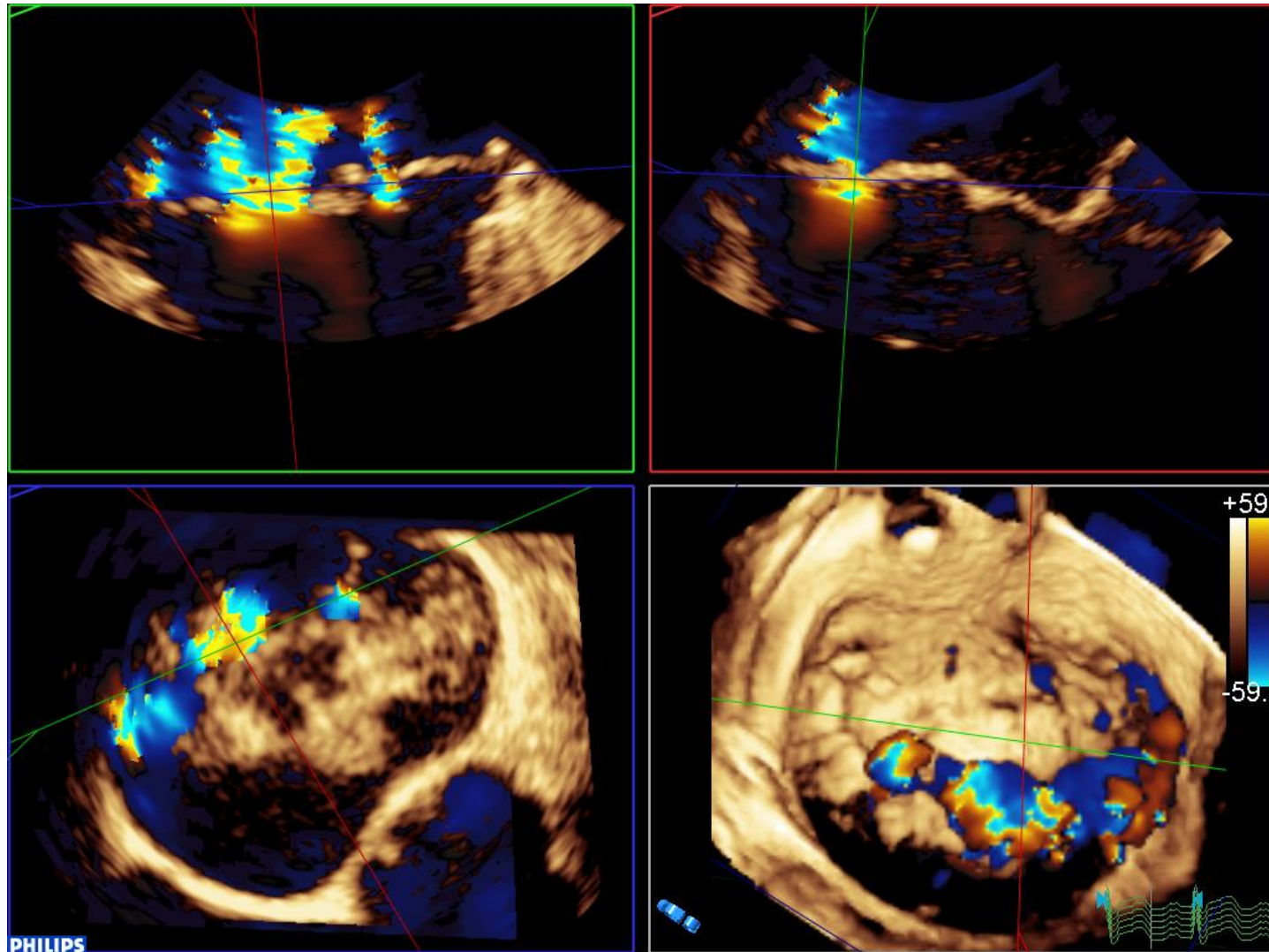
Multiple Leaks – 3D Actual Regurgitant Orifice Areas



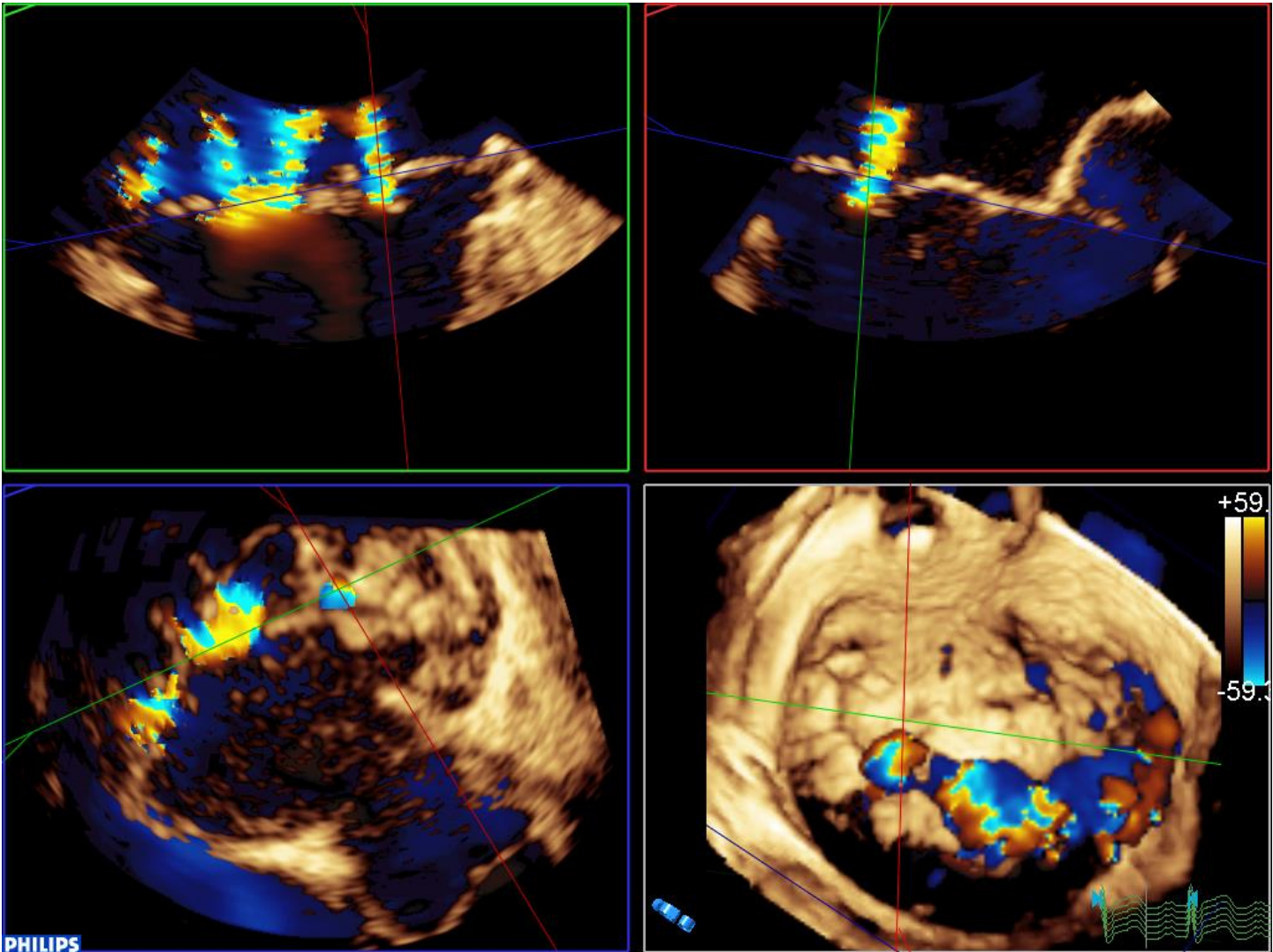
Multiple Leaks – 3D Actual Regurgitant Orifice Areas



Multiple Leaks – 3D Actual Regurgitant Orifice Areas



Multiple Leaks – 3D Actual Regurgitant Orifice Areas



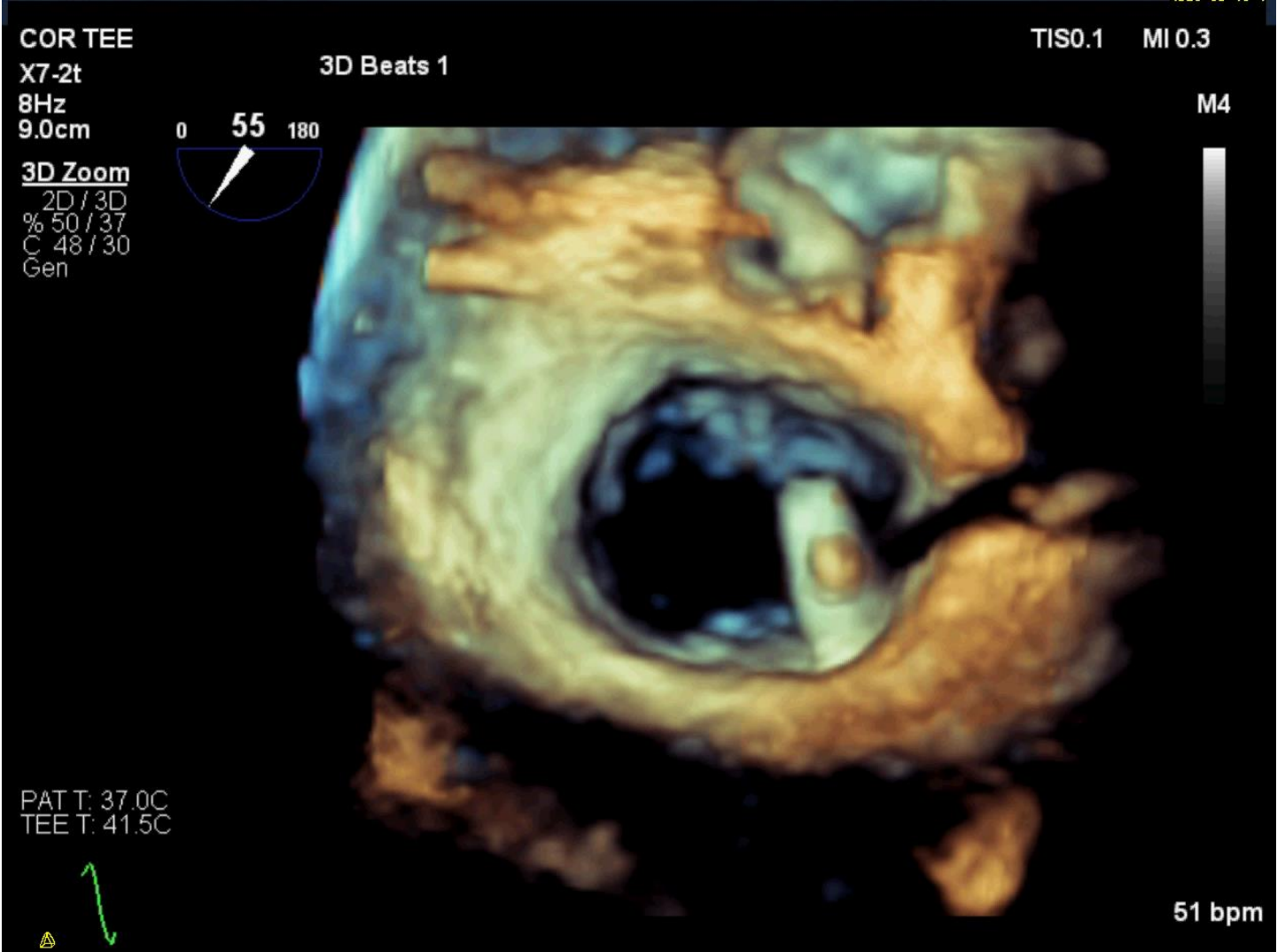
How 3D Images Change What We Do

2. Intra-procedural

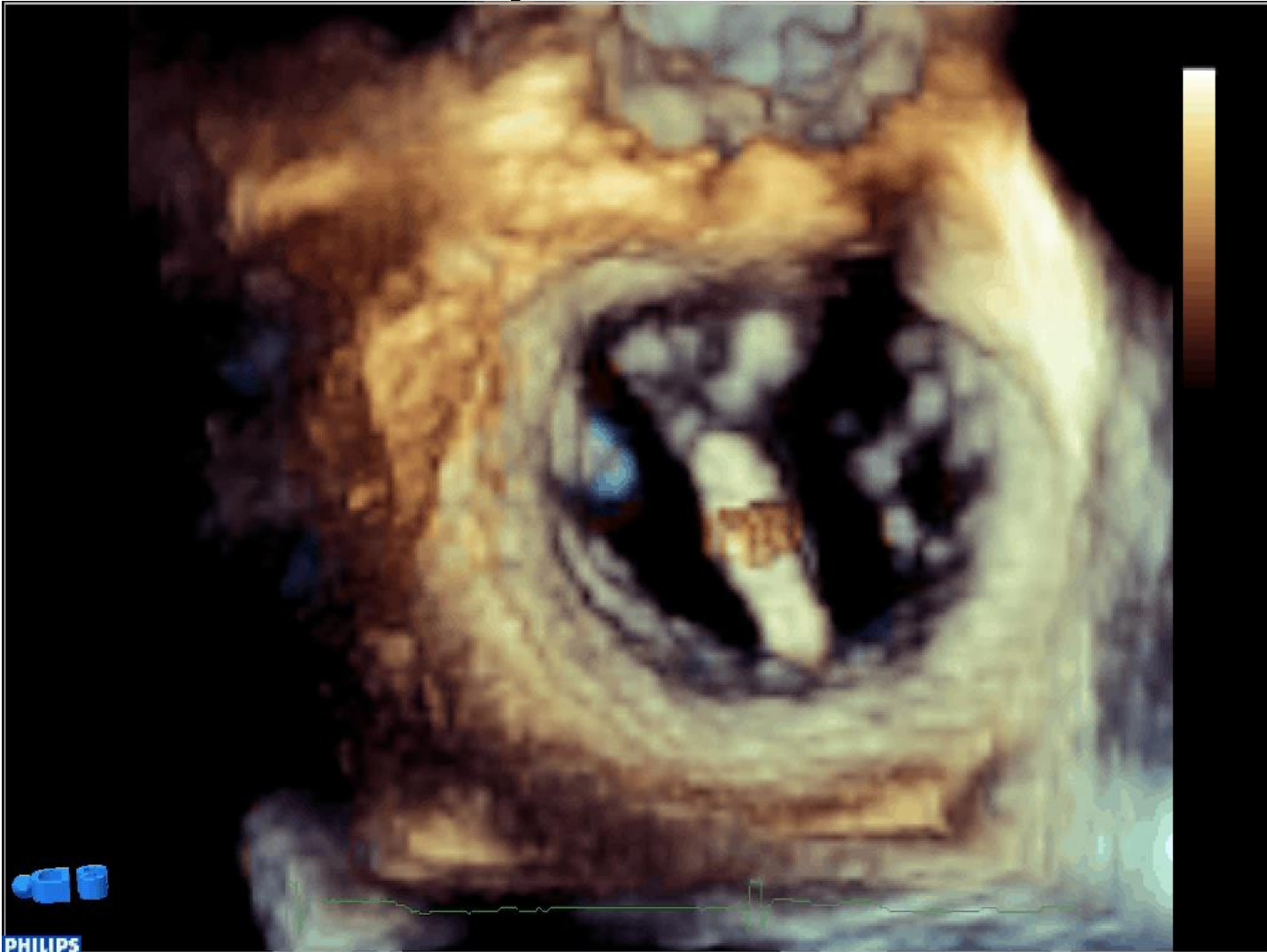- Clip alignment and positioning
 - What part of the leak are you targeting?
 - If multiple clip strategy, where are you pushing that leak
 - Rotation – Perpendicular to line of coaptation
- More clips?
 - Locate the residual leak before letting go
 - Locate the residual leak after letting go



Clip Position



Clip Rotation

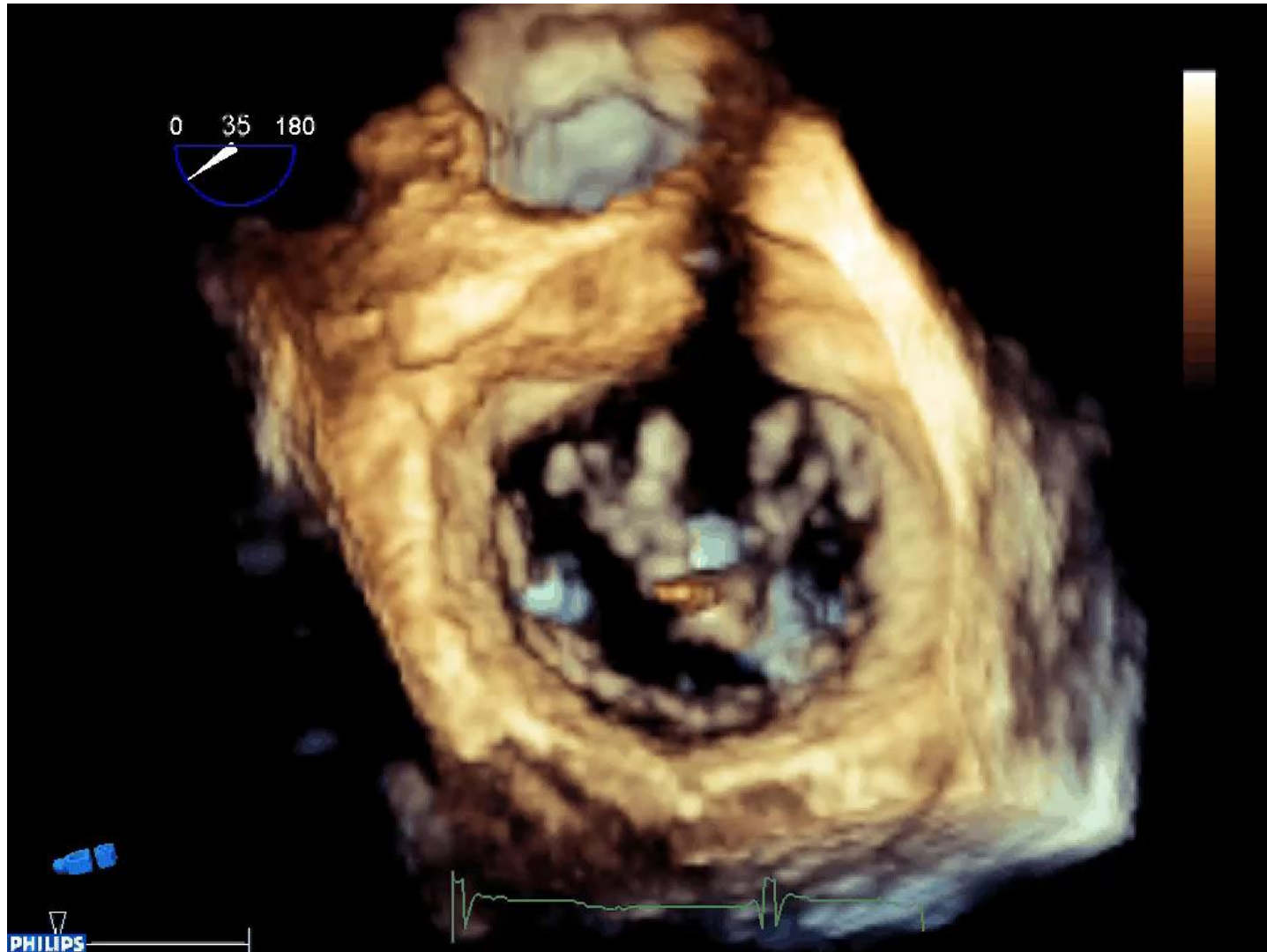


PHILIPS

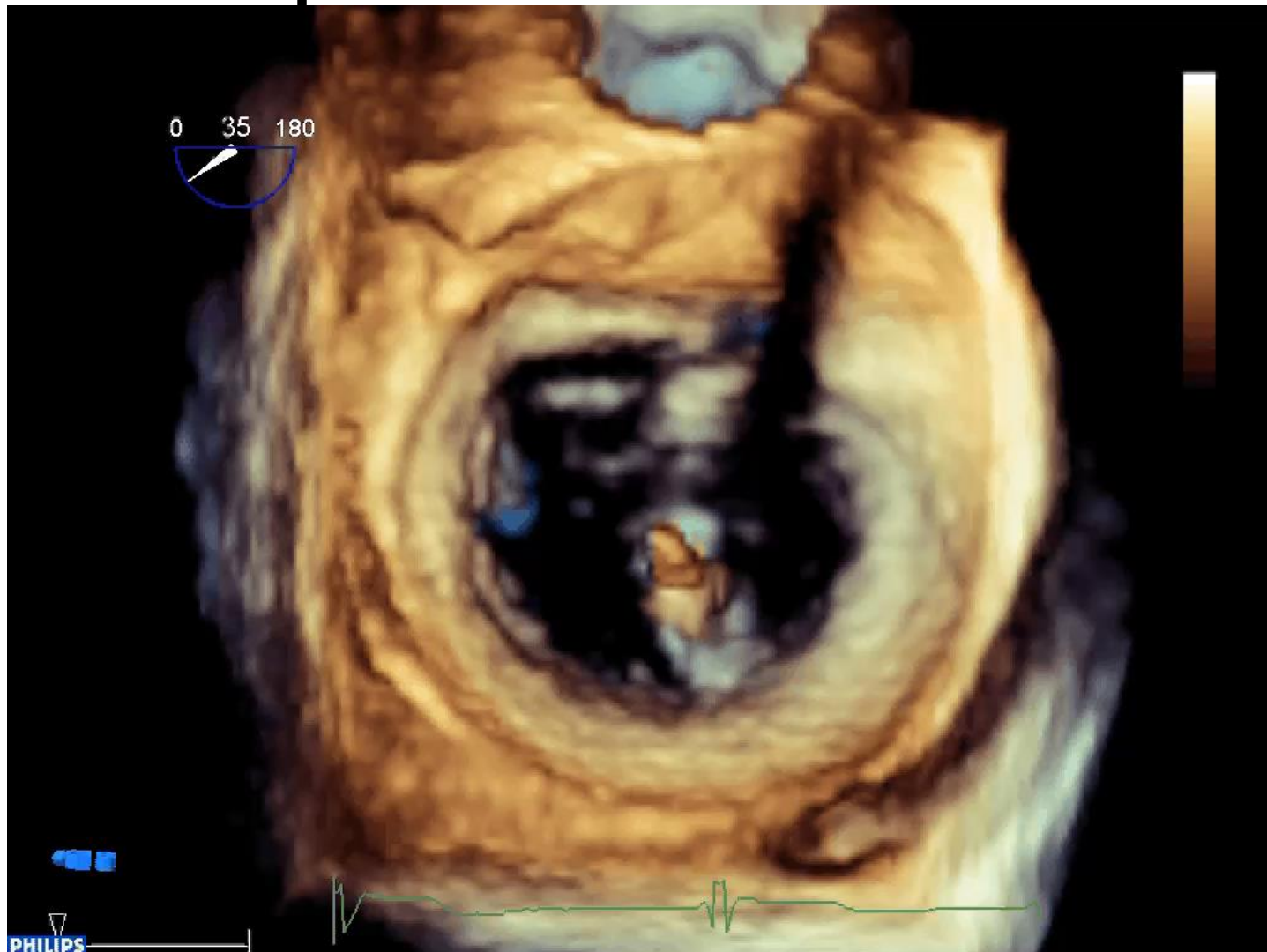

UNIVERSITY OF OTTAWA
HEART INSTITUTE
INSTITUT DE CARDIOLOGIE
DE L'UNIVERSITÉ D'OTTAWA

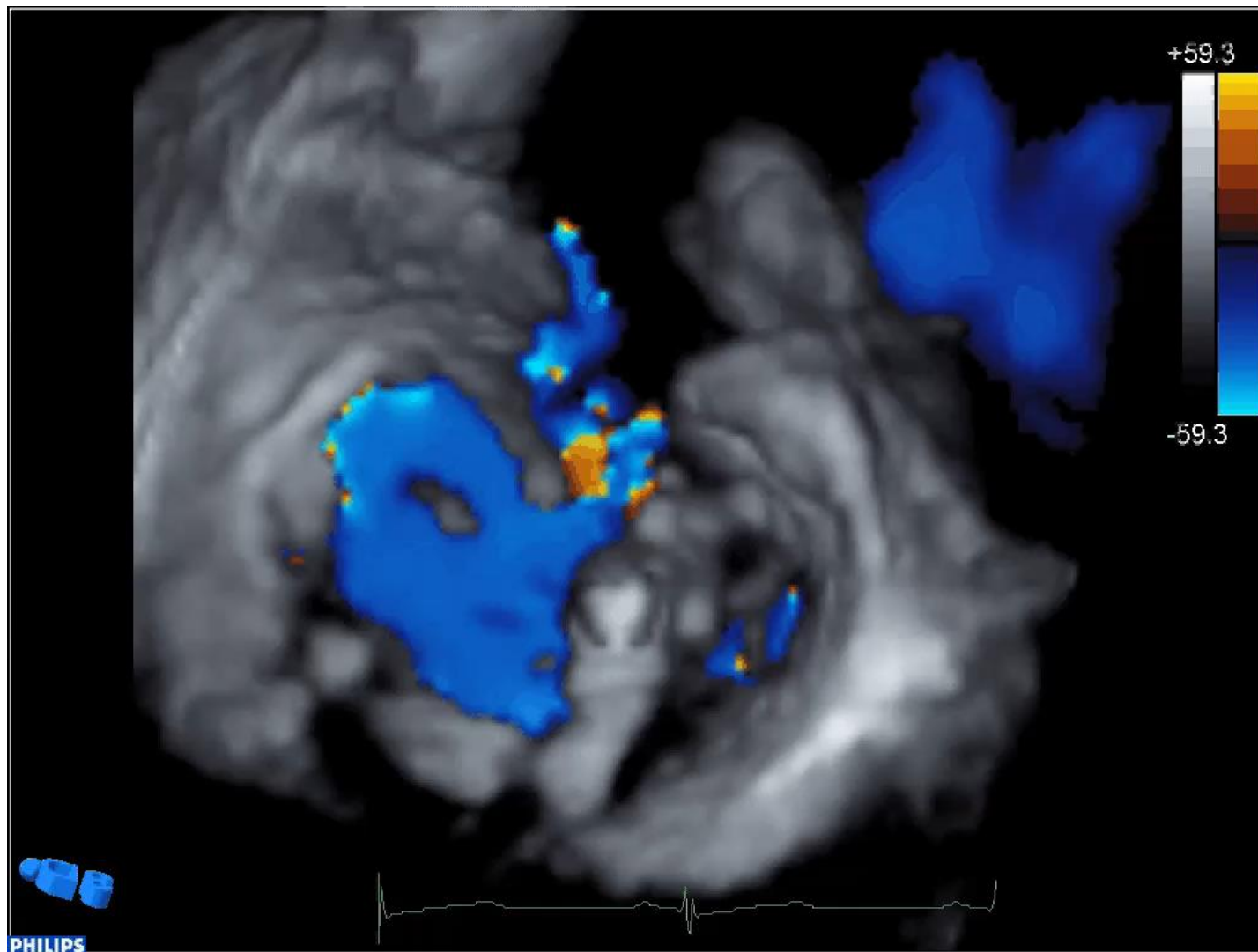
Clip Rotation Across Valve



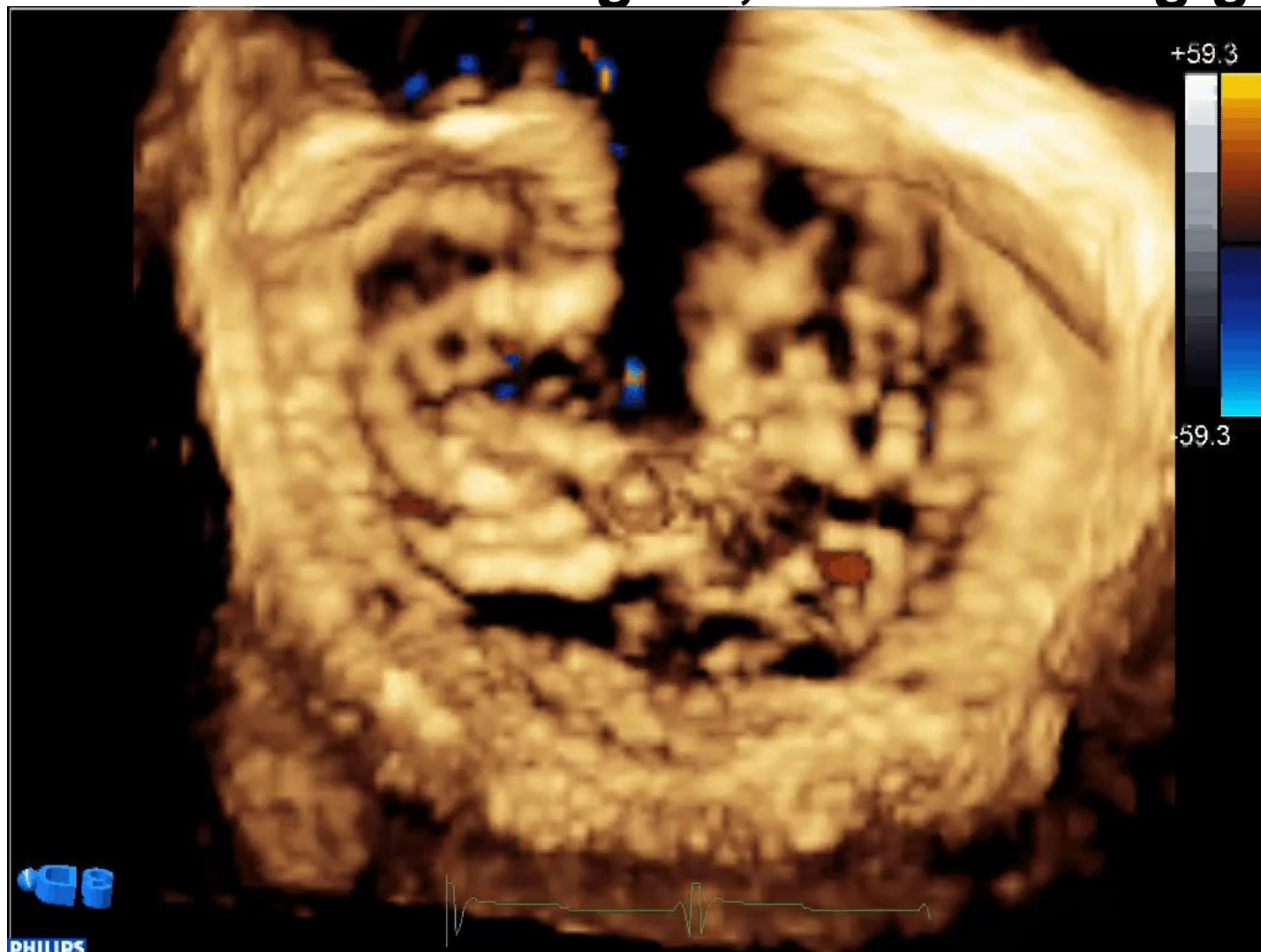
Better (but not yet ideal) Clip Rotation Across Valve



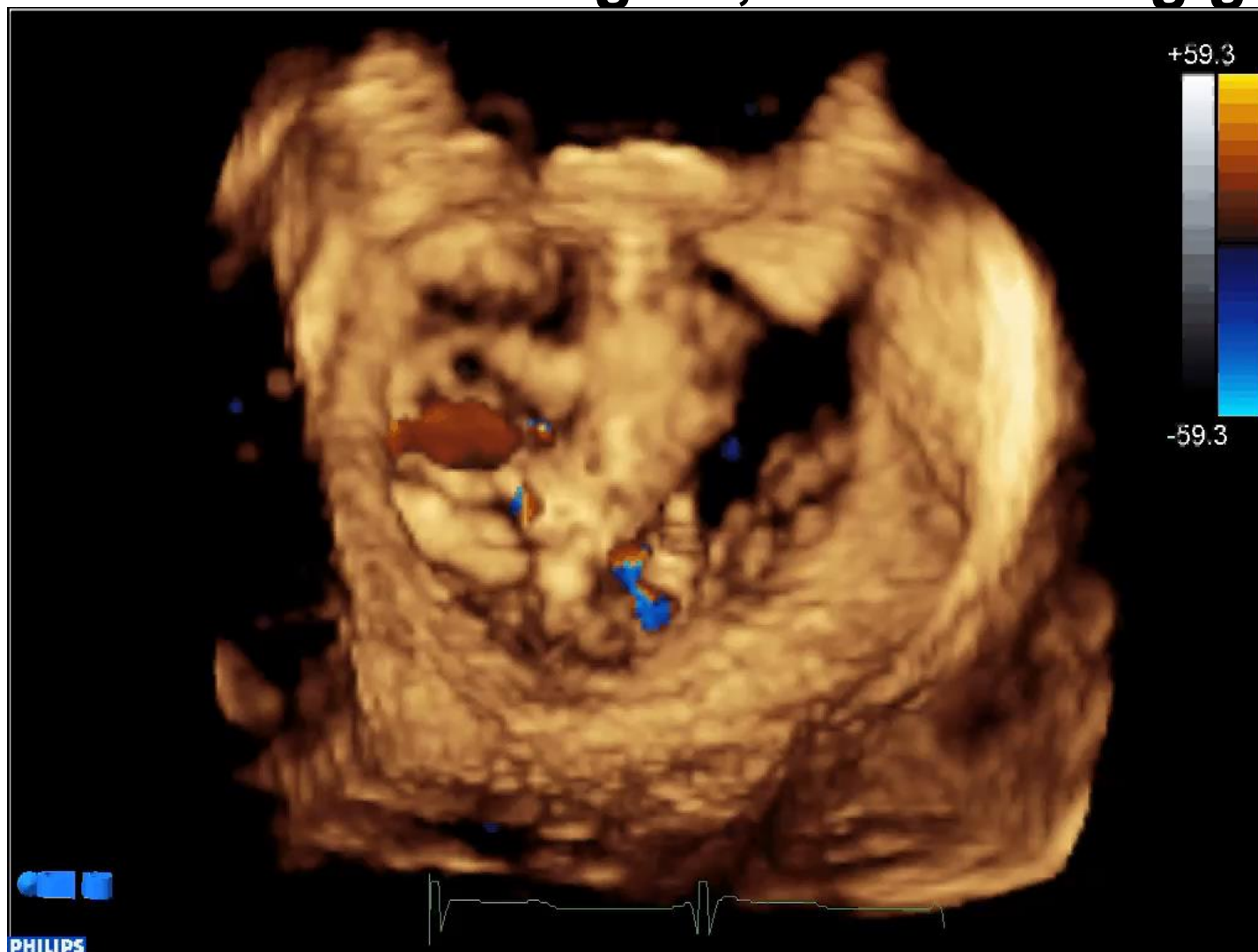
Residual leak after grab, before letting go



Residual leak after grab, before letting go



Residual leak after grab, before letting go



How 3D Images Change What We Do

3. Post-procedural

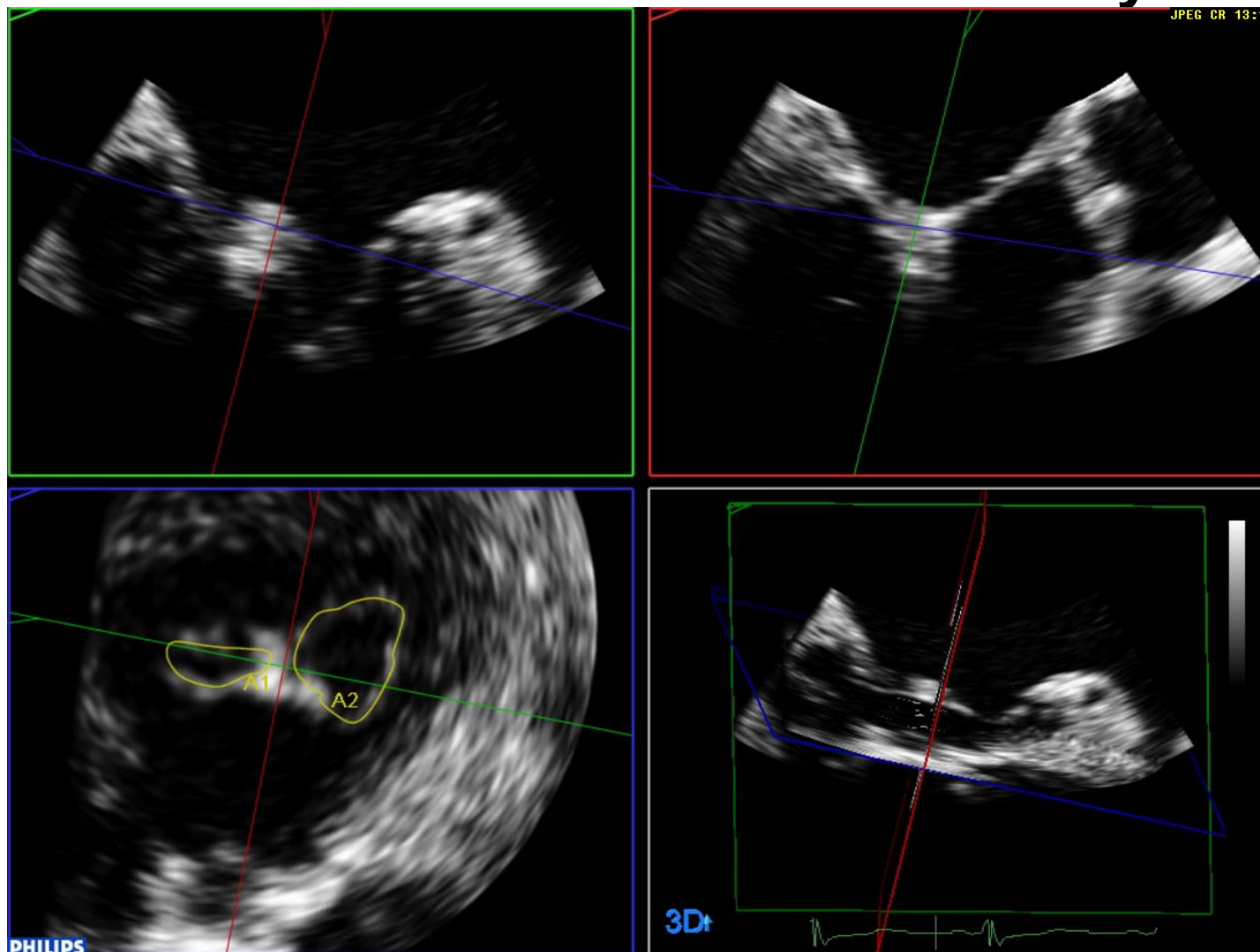
- Leak quantification
 - Actual Regurgitant Orifice Area
 - Multiplanar Reconstruction from 3D Colour Dataset
- Mitral Valve Area
 - 3D Planimetry
 - Multiplanar Reconstruction from 3D Dataset



Leak Quantification – 3D AROA



Mitral Valve Area – 3D Planimetry



How 3D Images Change What We Do

1. Pre-procedural

- Anatomy, anatomy, anatomy
- Localizing the leak

2. Intra-procedural

- Clip alignment and positioning
- More clips?

3. Post-procedural

- Leak quantification
- Mitral Valve Area





UNIVERSITY OF OTTAWA
HEART INSTITUTE

INSTITUT DE CARDIOLOGIE
DE L'UNIVERSITÉ D'OTTAWA

Thank you!
